

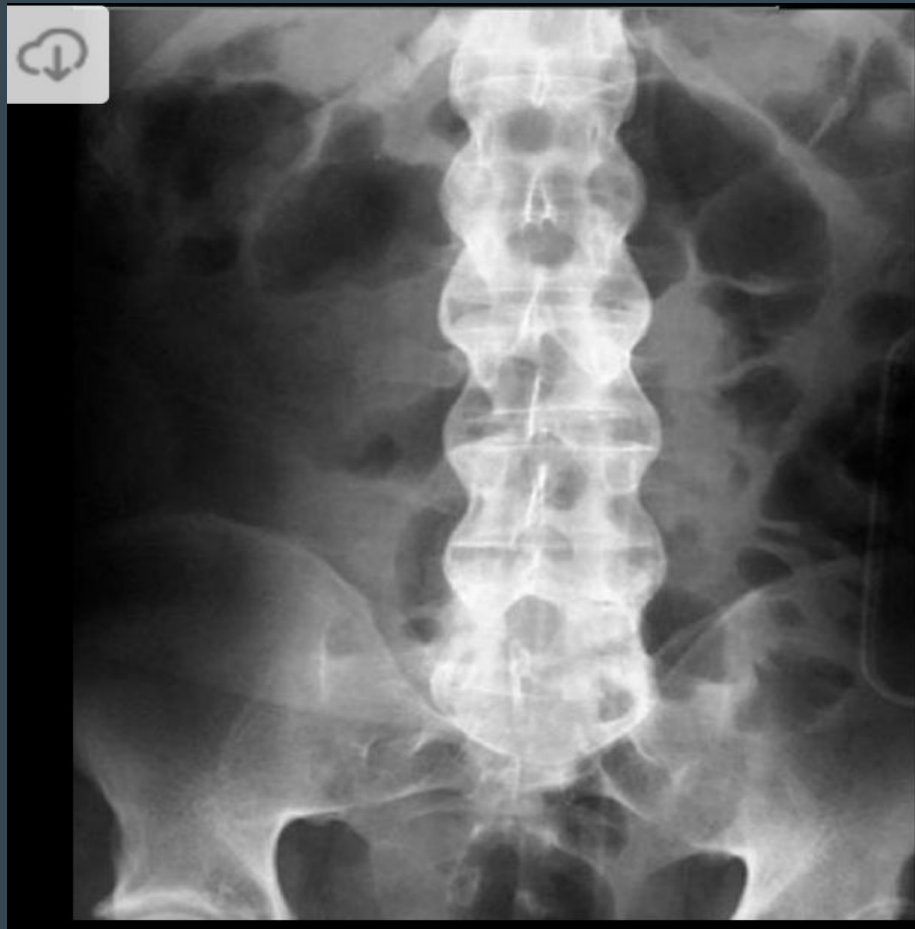# Divine Intervention Episode 26

## USMLE Radiology

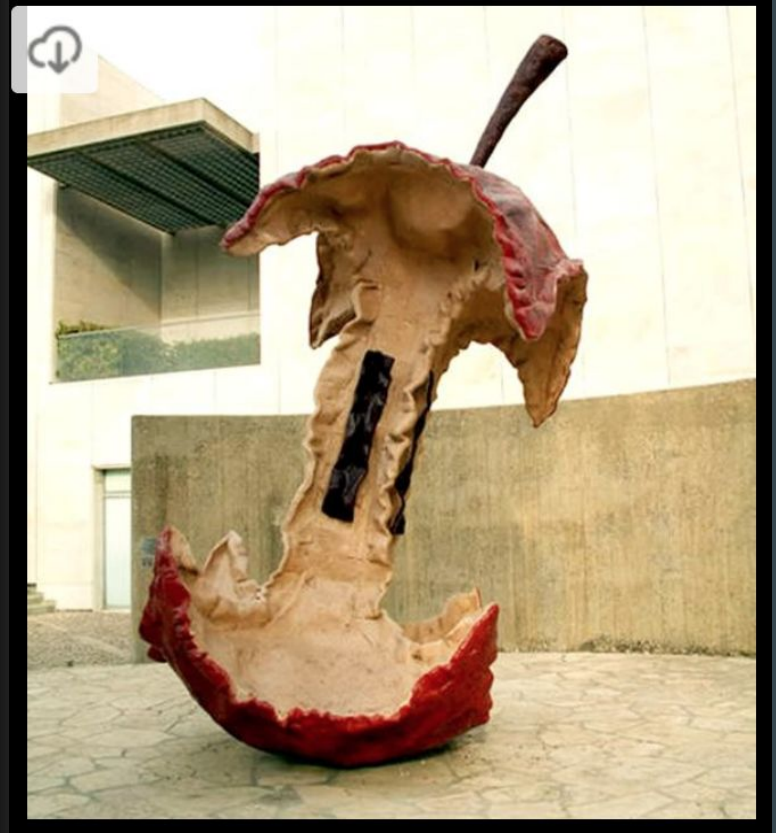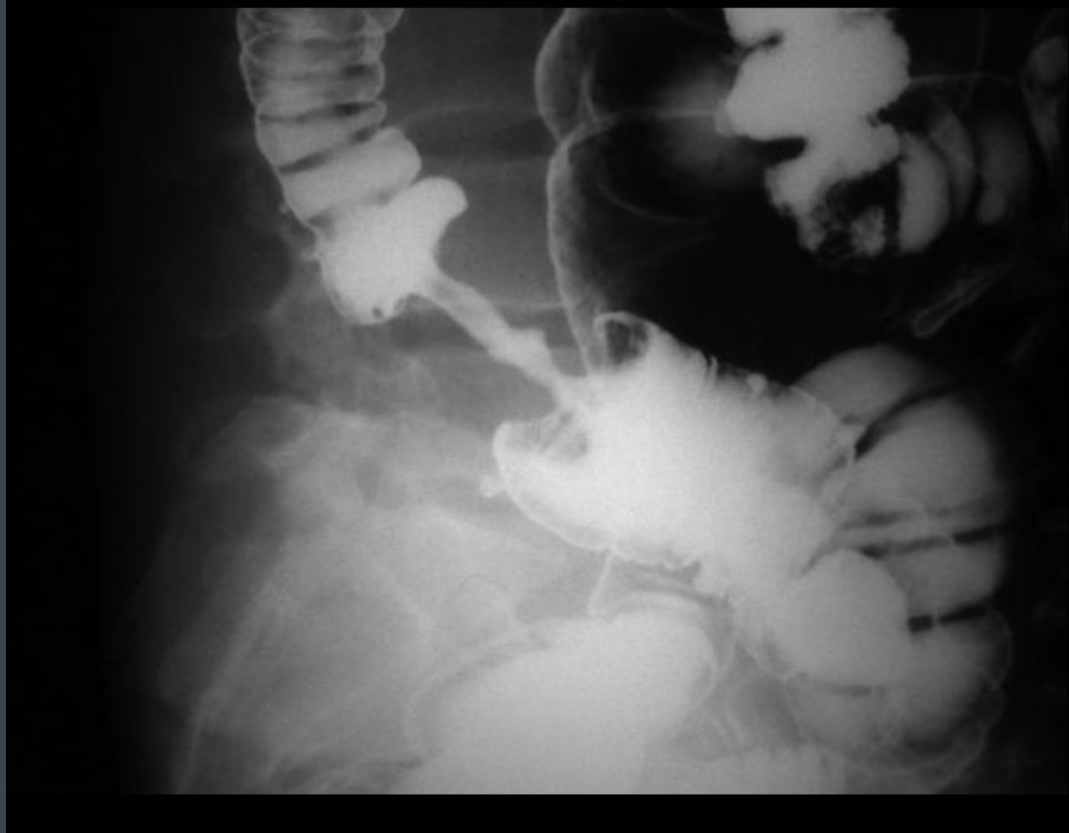...

Some MS4


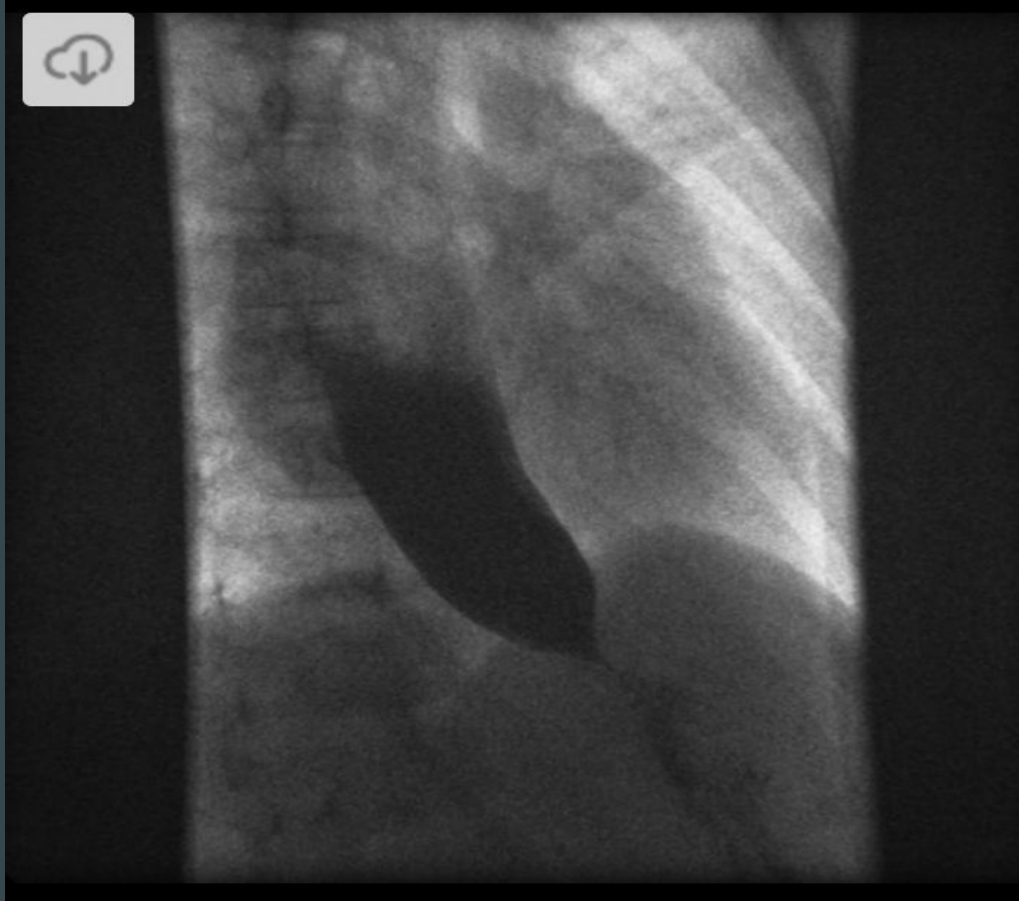
1



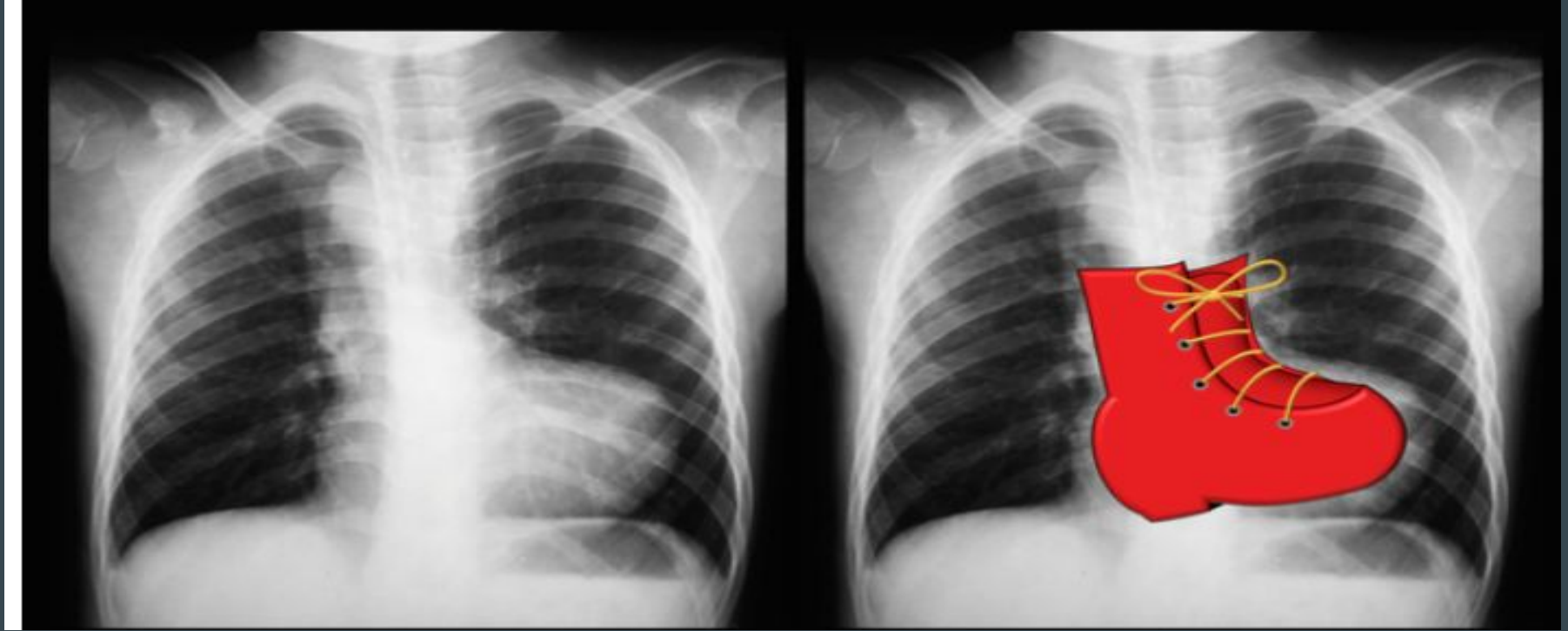
2-55 yo M with Heme+ stools and Hb of 6.9



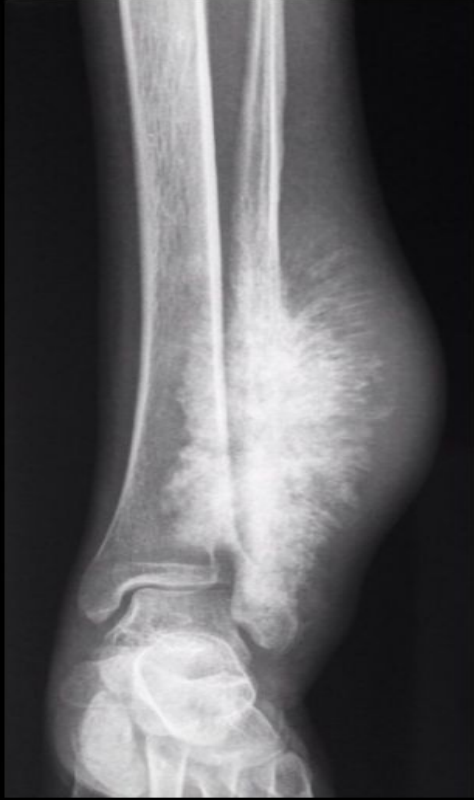# 3-Presents with Dysphagia to Solids and Liquids



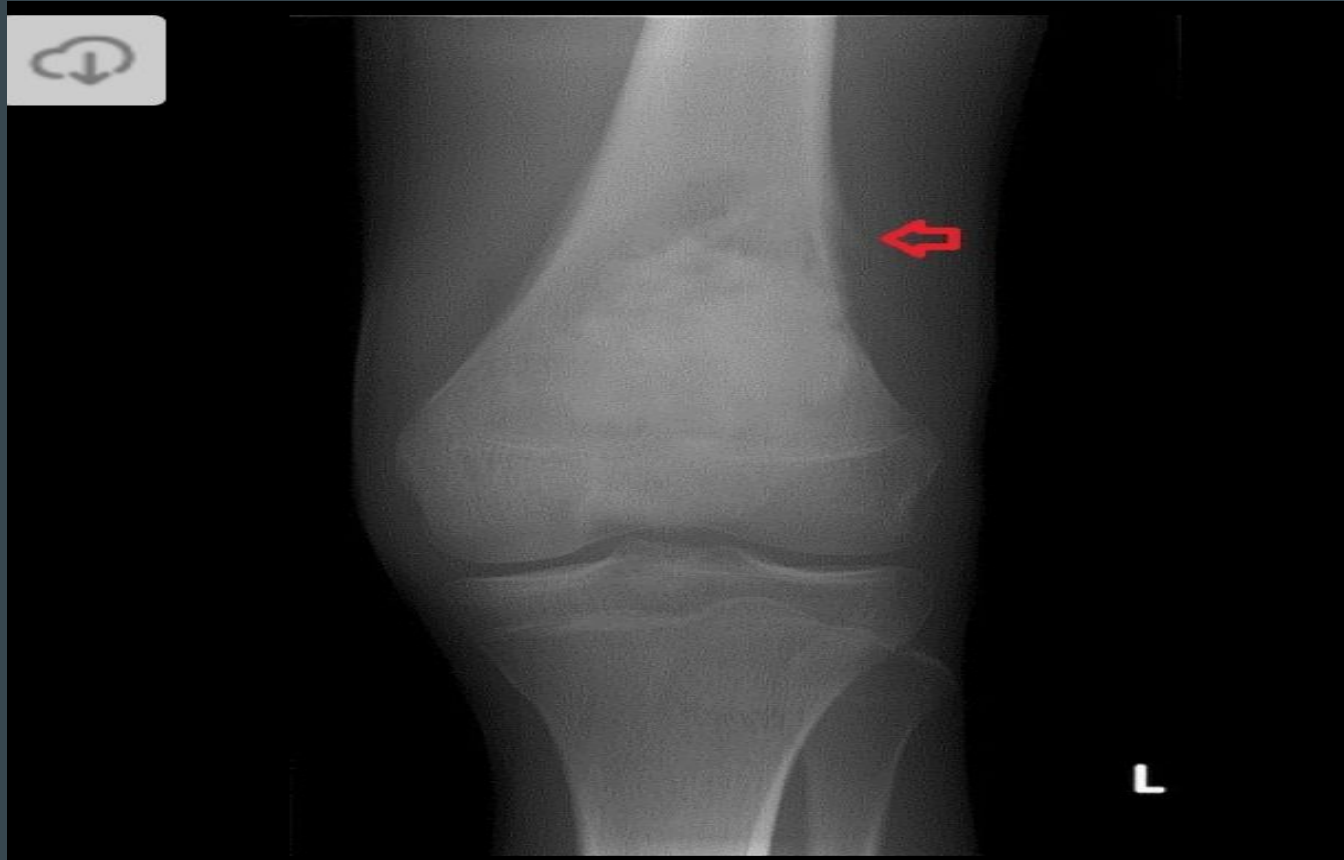
## 4-This child was born with hypocalcemic seizures



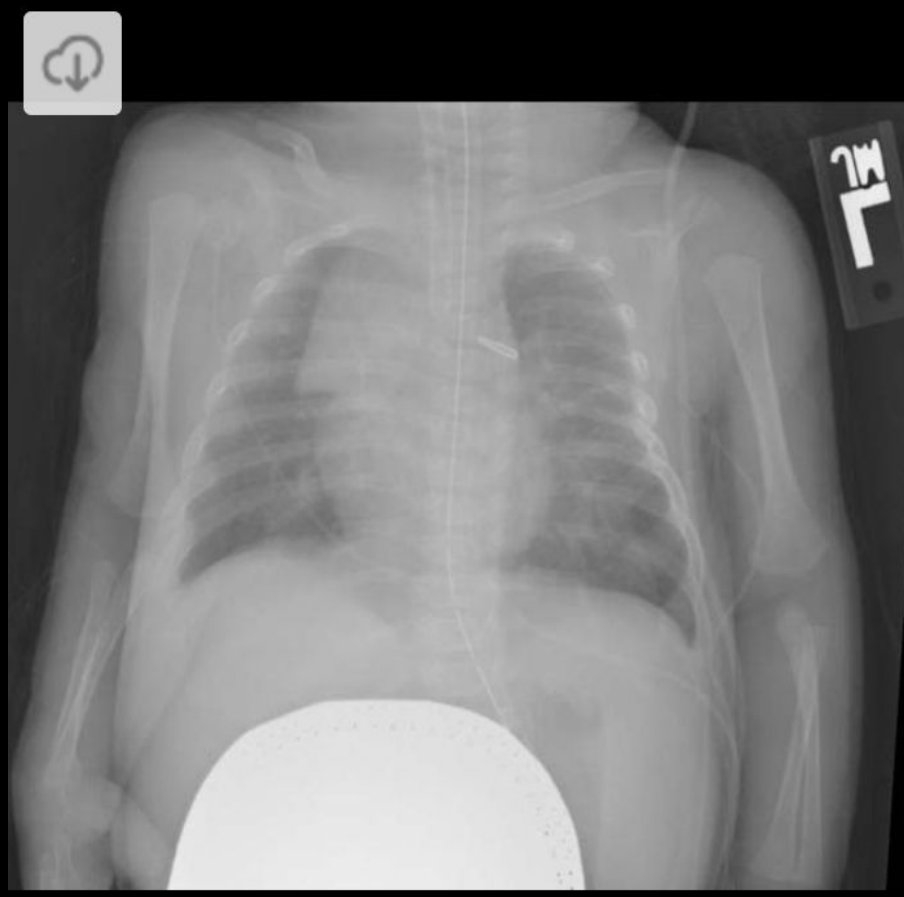# 5A-This child had a white reflex at birth



# 5B-This child had a white reflex at birth


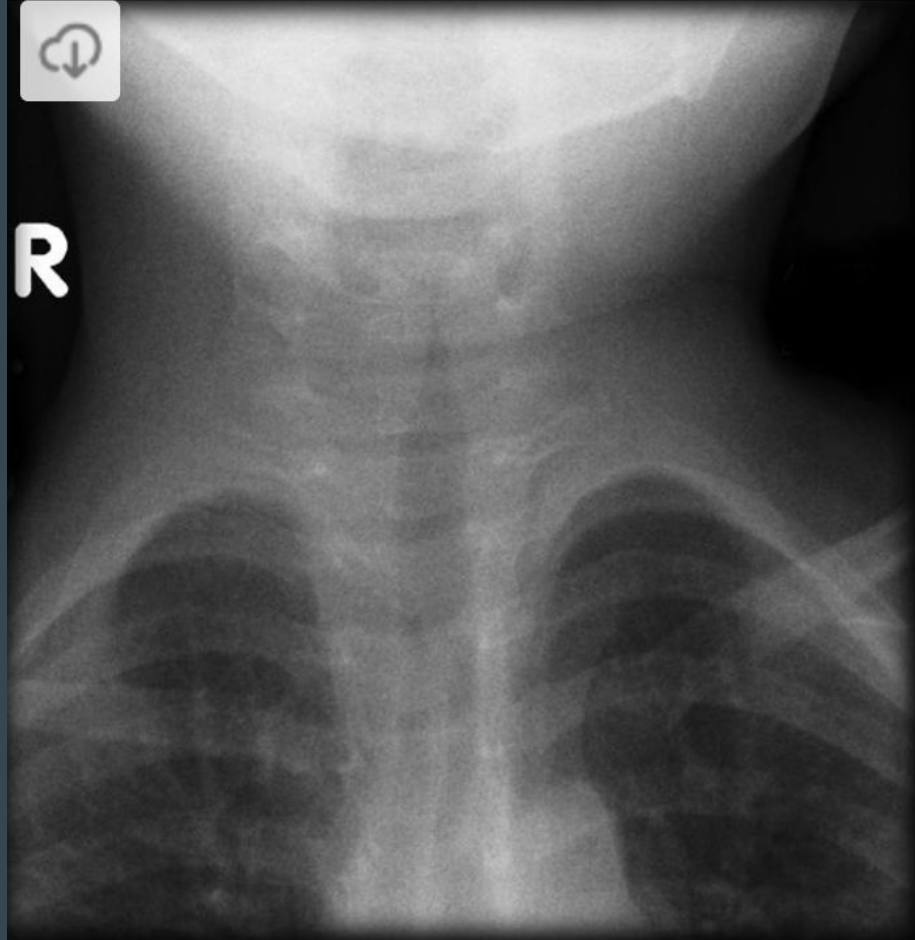


6-APGAR scores were 9 and 10 at 1 and 5 mins respectively

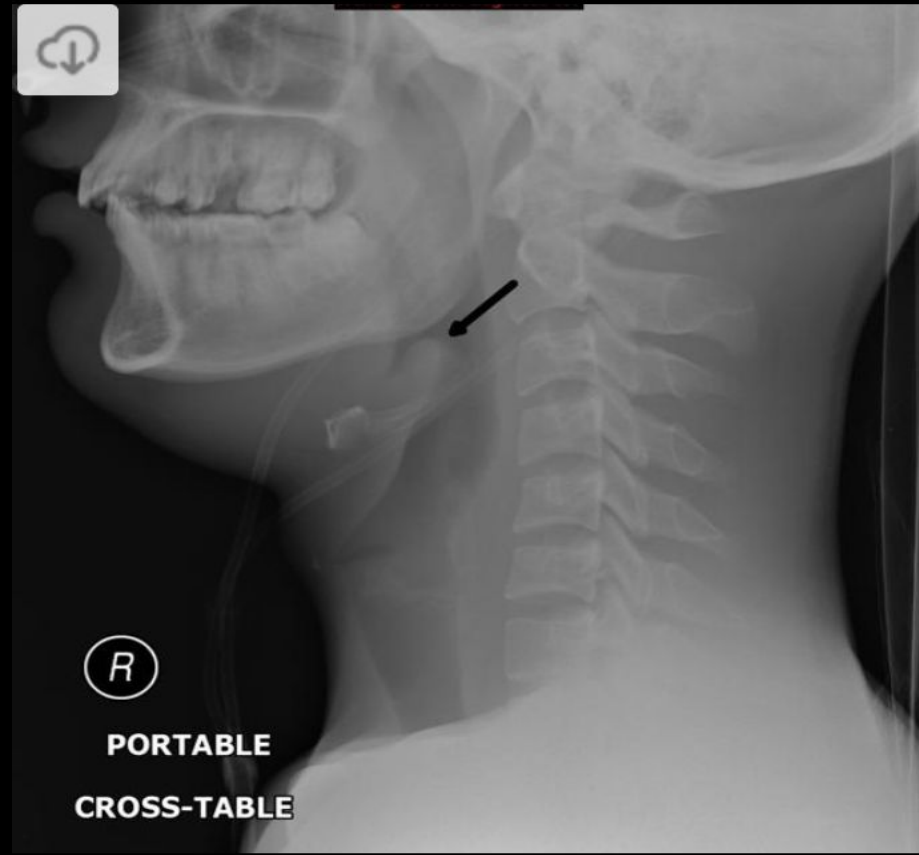
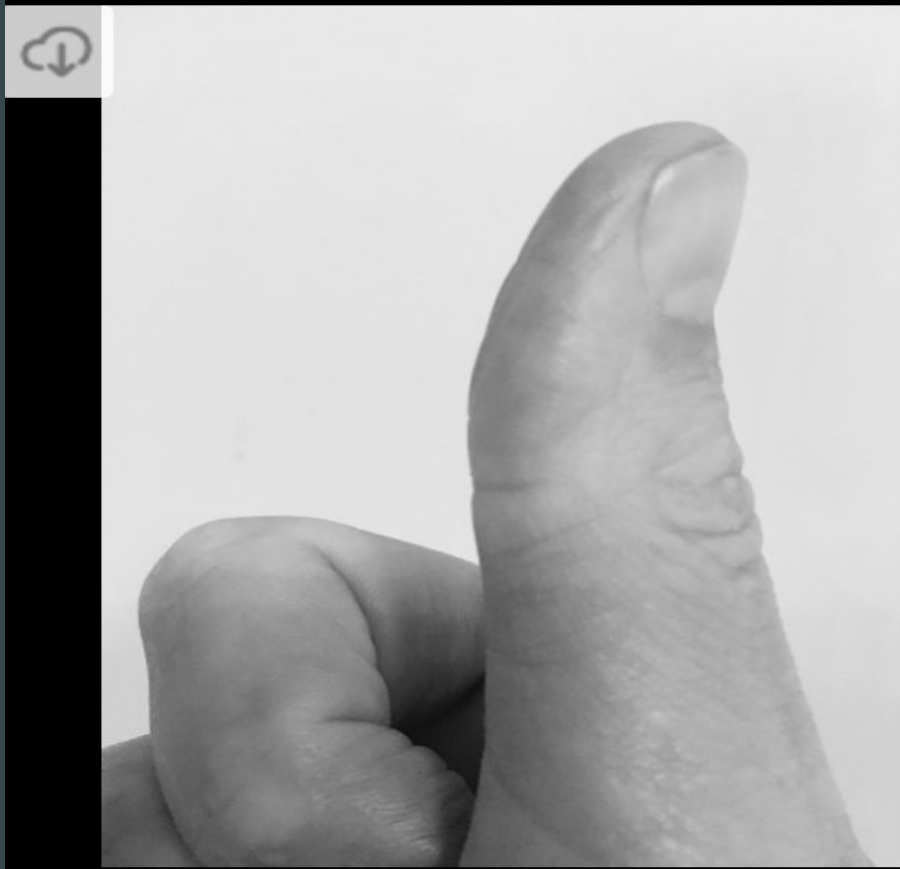



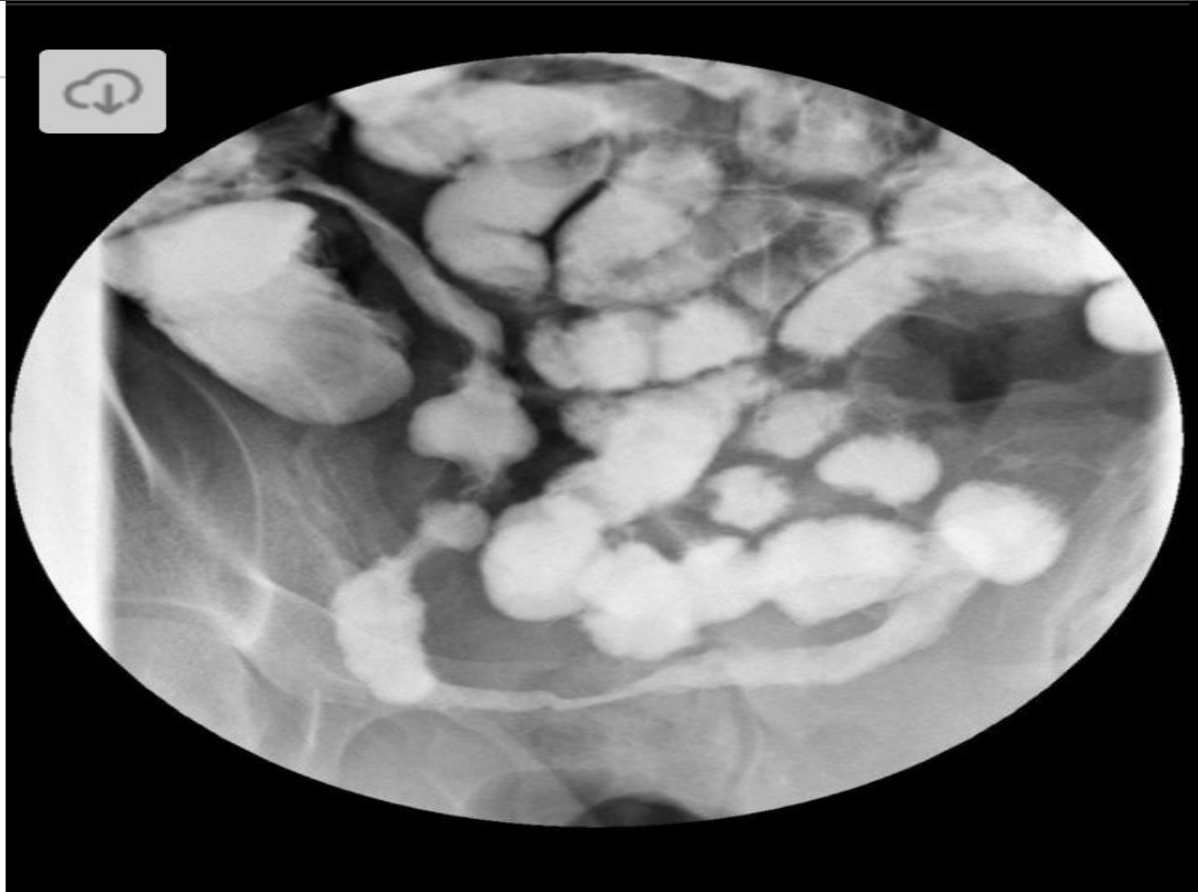# 7-This child presented to the ED with wheezing



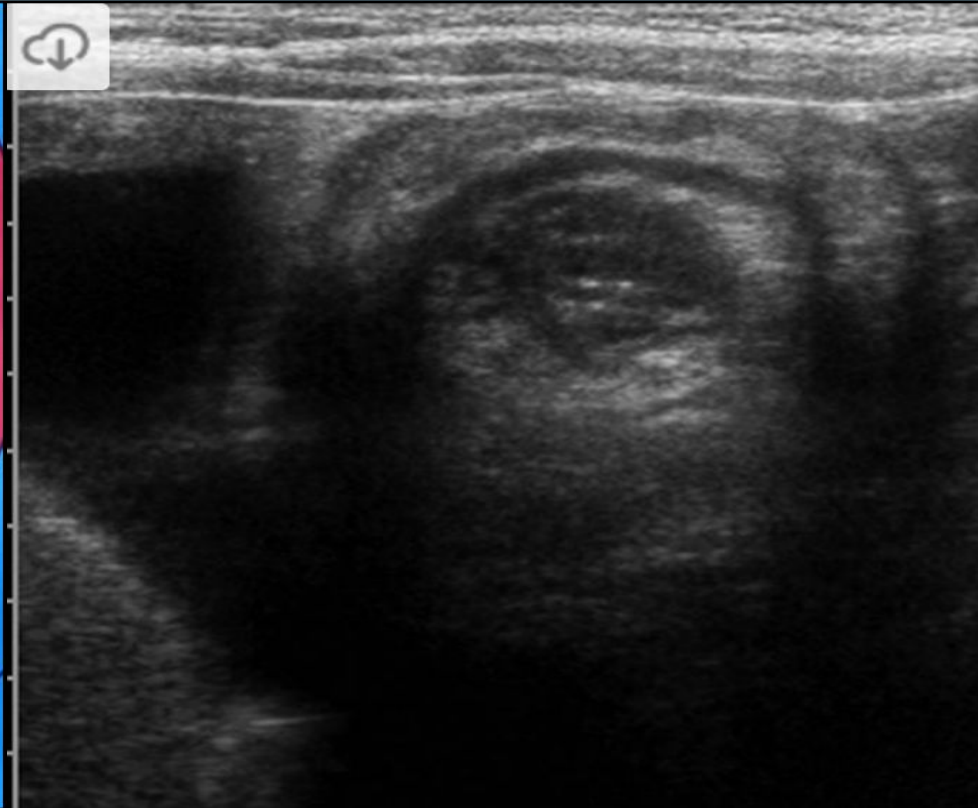

# 8-This child is drooling, T of 104, Wheezing



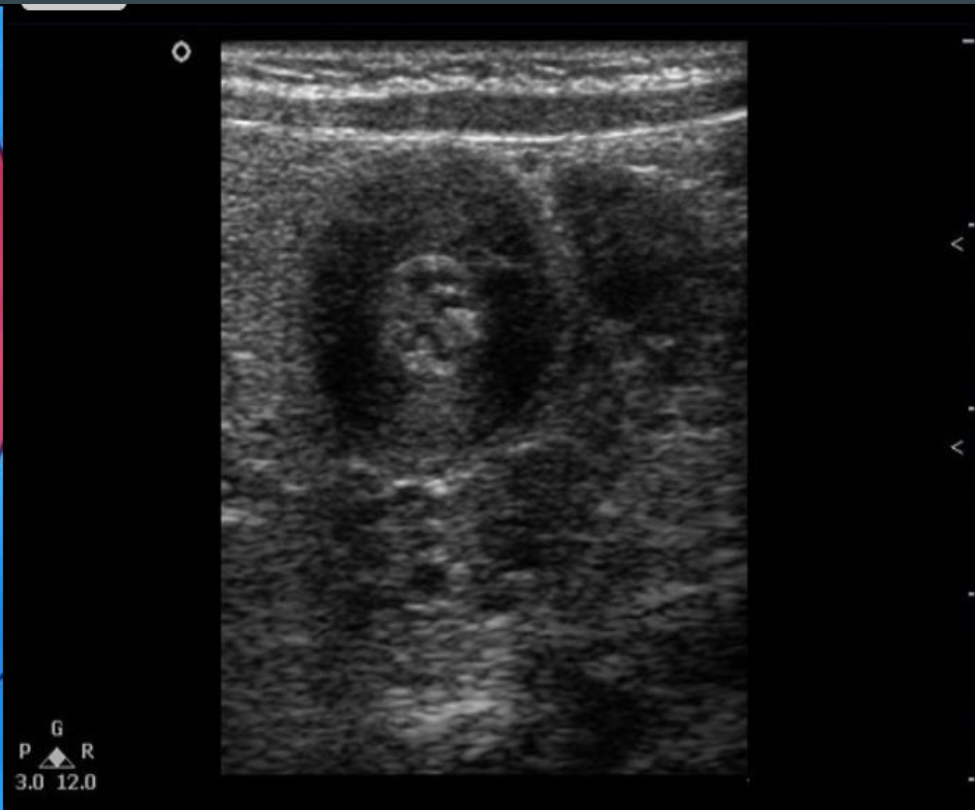
# 9-This patient has a B12 deficiency



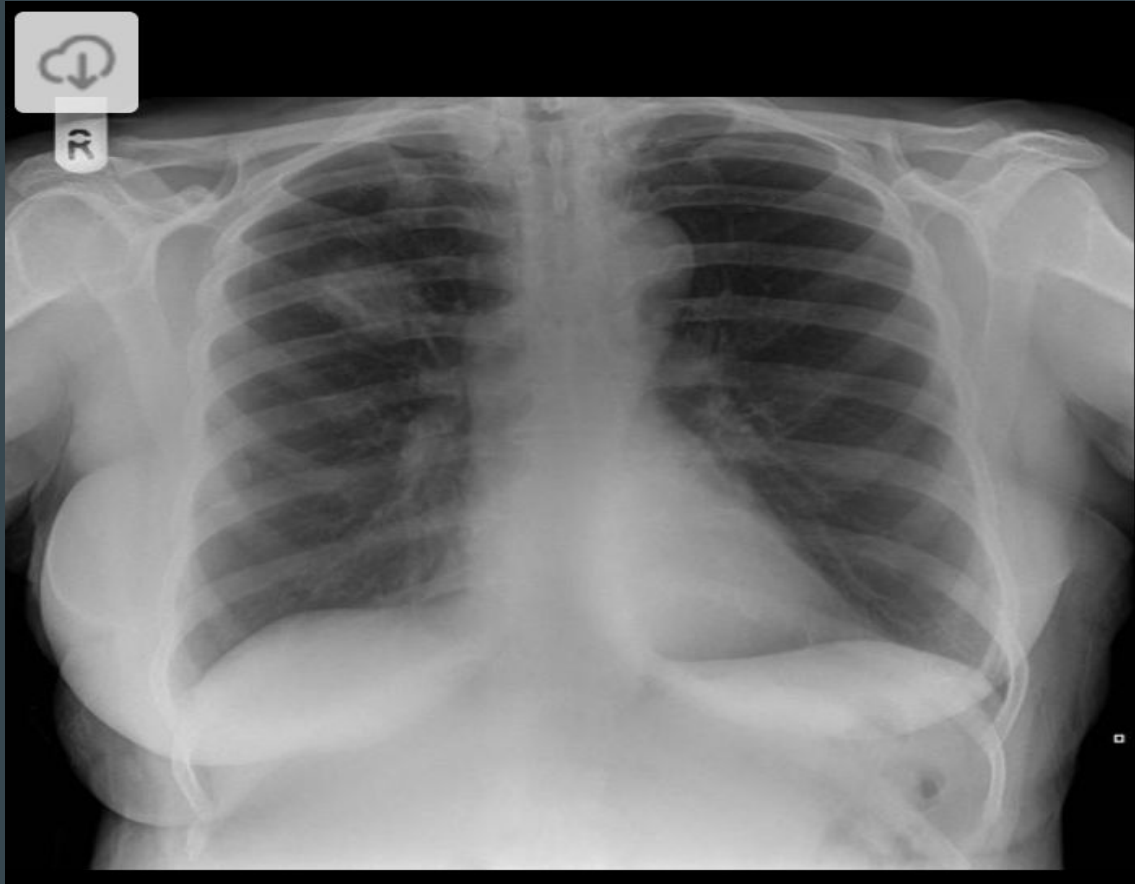
# 10-Red currant jelly stools in a child



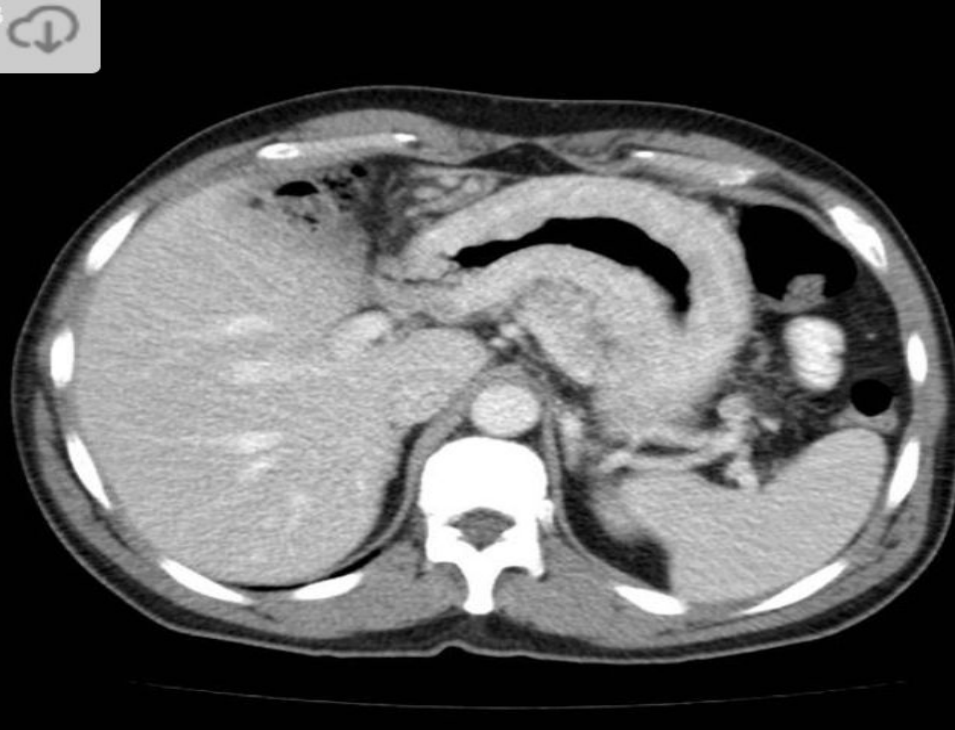# 11-Nonbilious vomiting in a newborn taking erythromycin



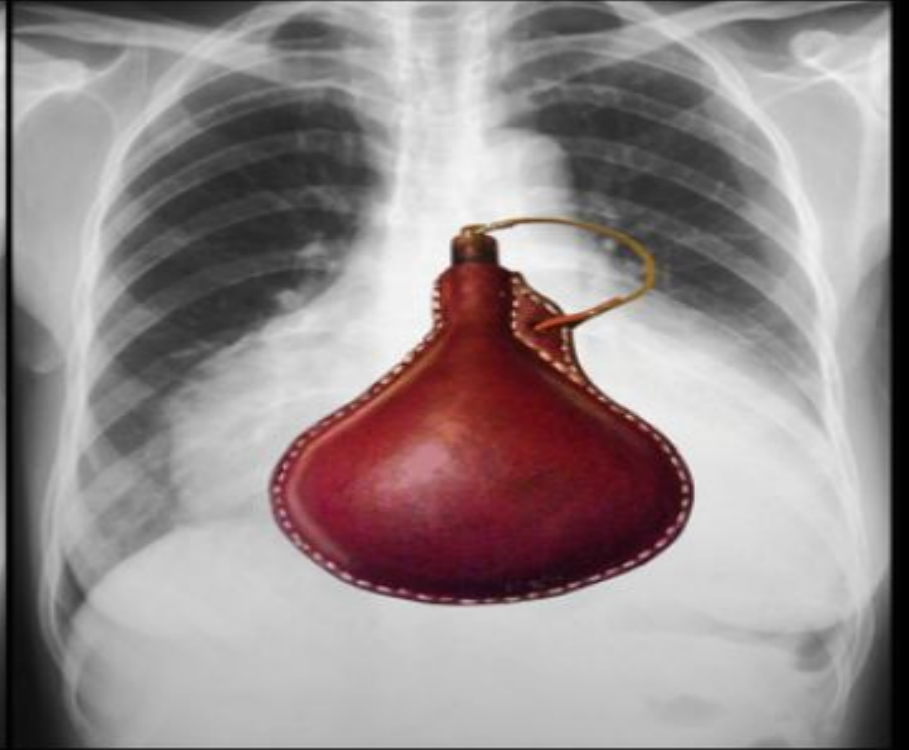
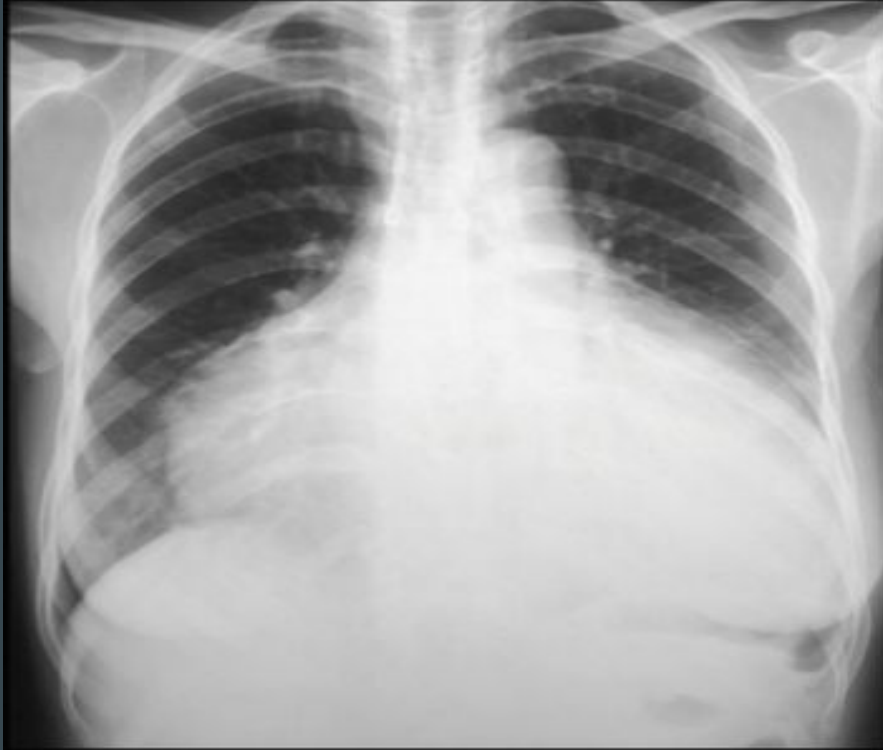# 12-200 pack year smoking history



13-50 lb weight loss in a 6 mo period

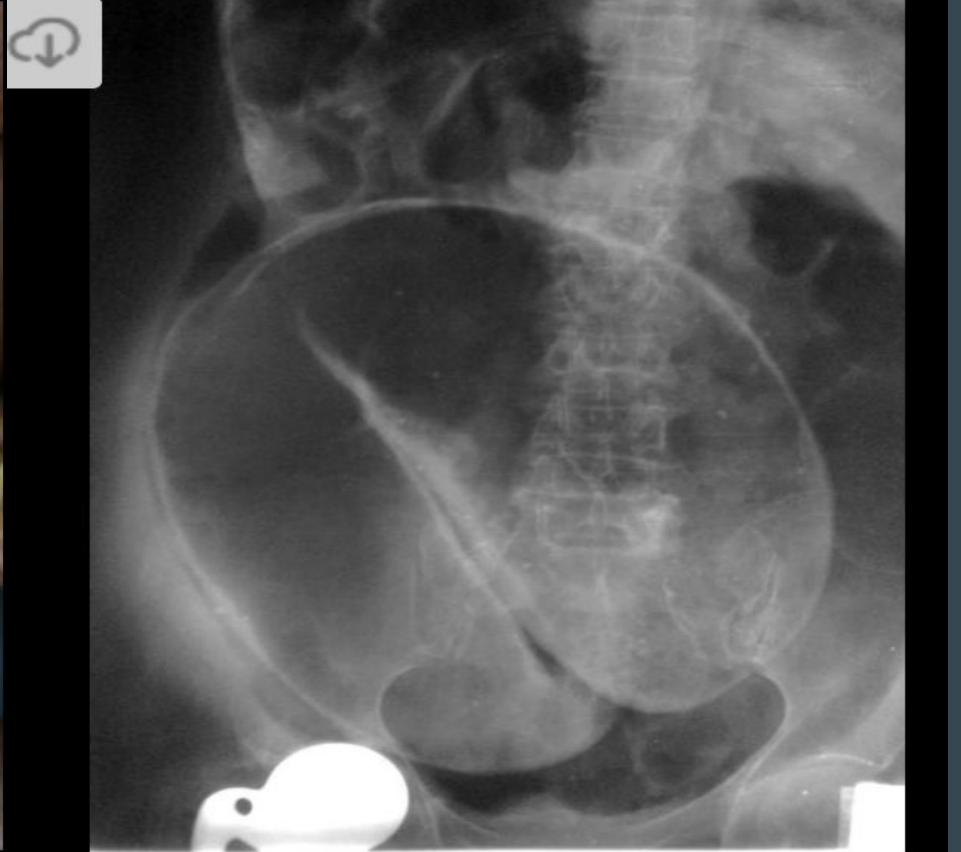

# 14-History of CHF

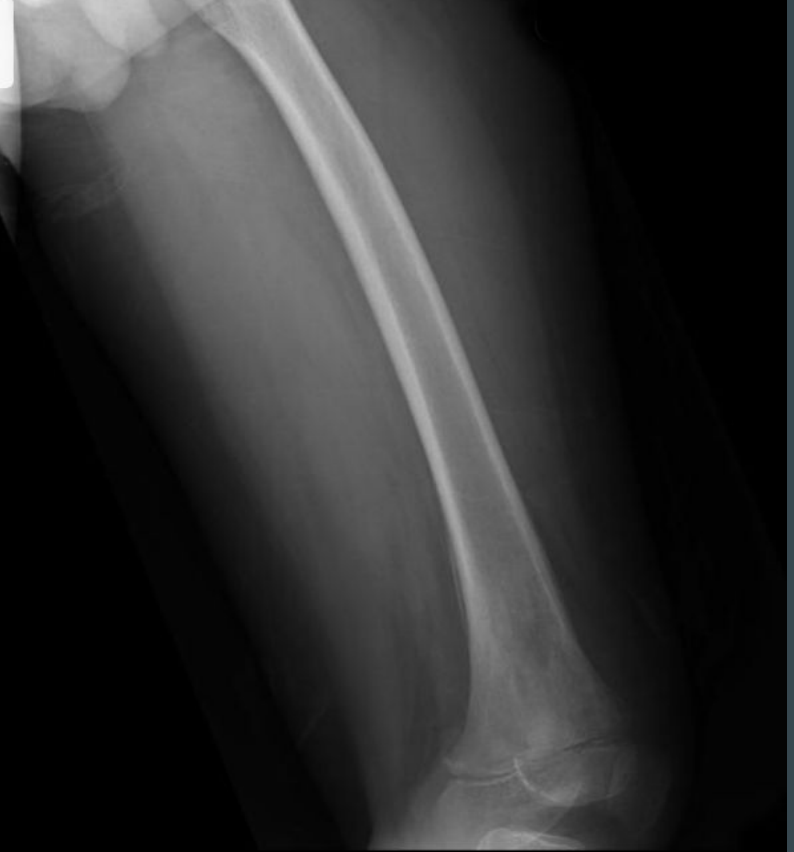



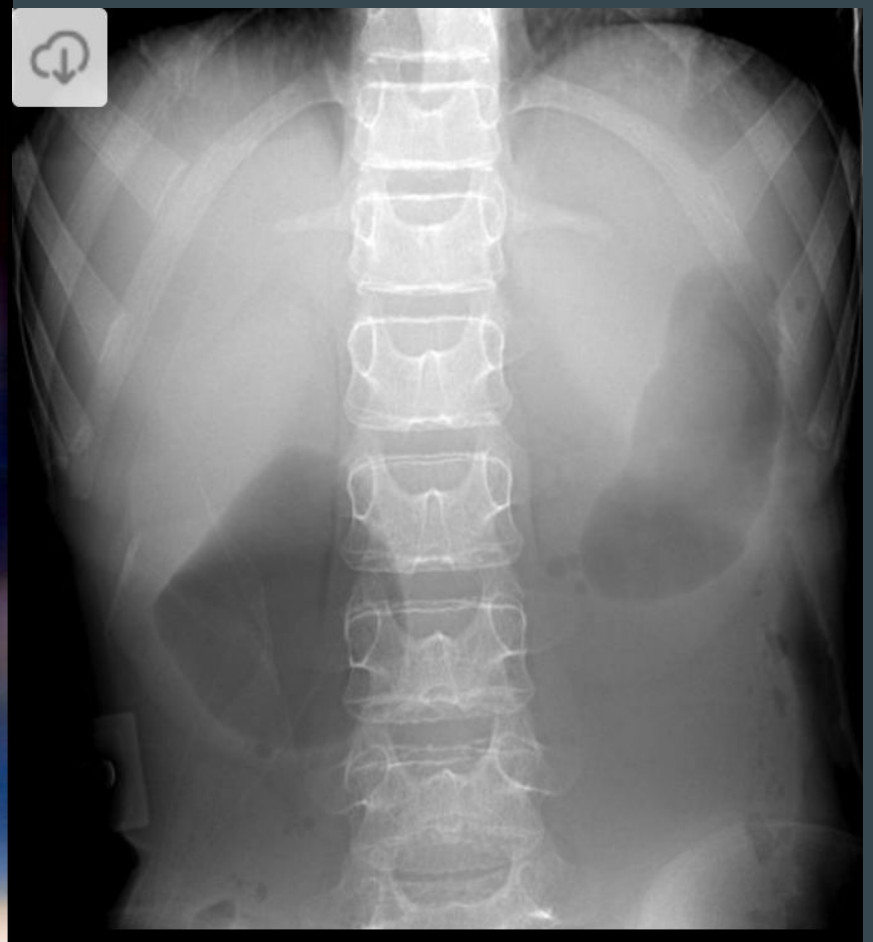

# 15-Severe abdominal pain and constipation



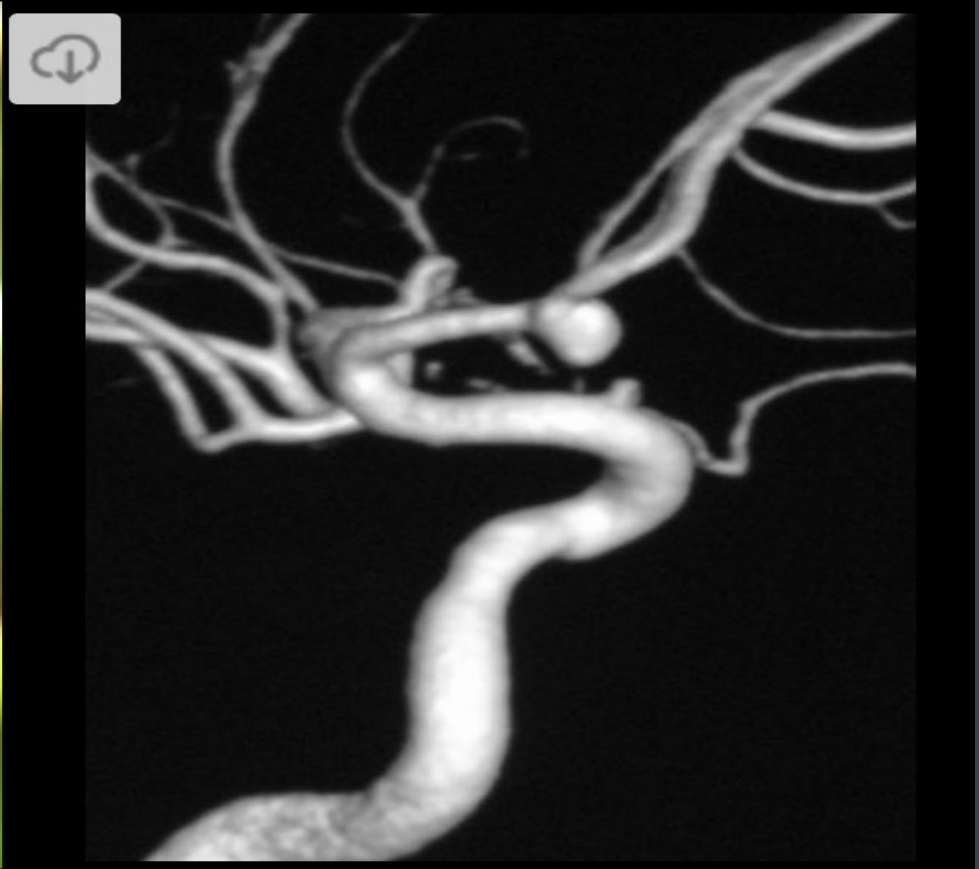16-12 yo with a 2 mo hx of fevers and leg pain



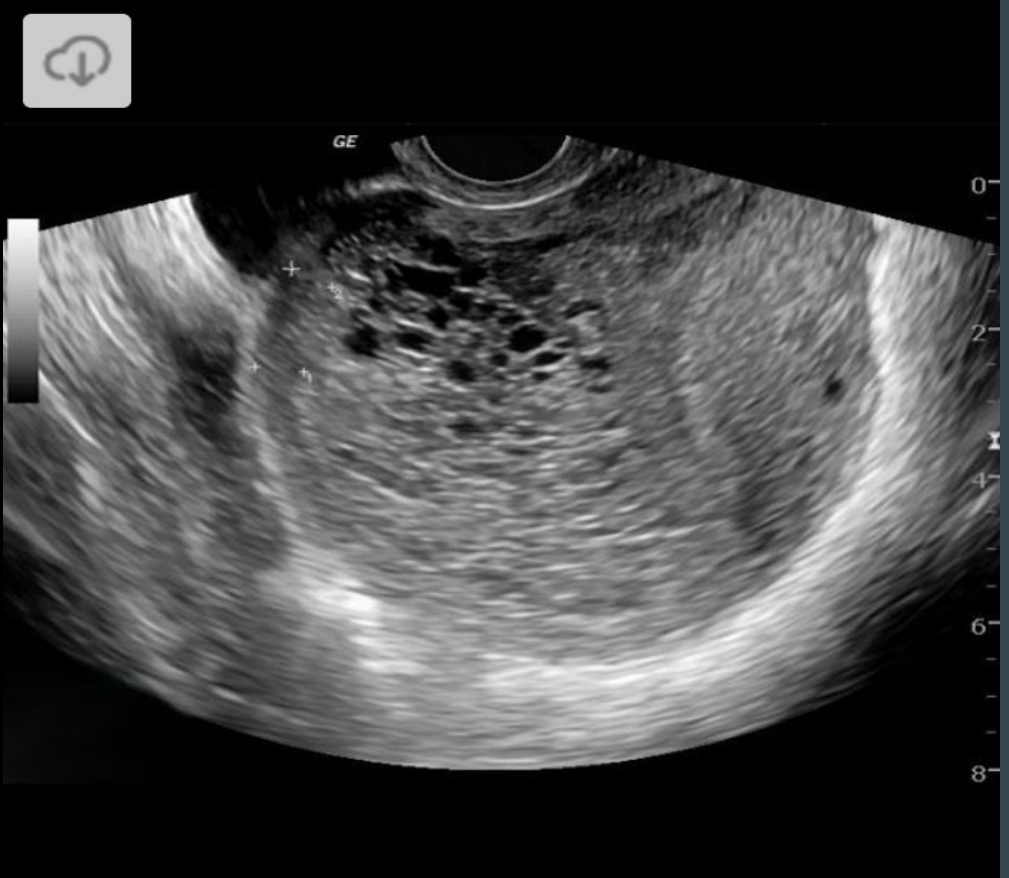# 17-This child has a history of Tri 21 + Bilious vomiting



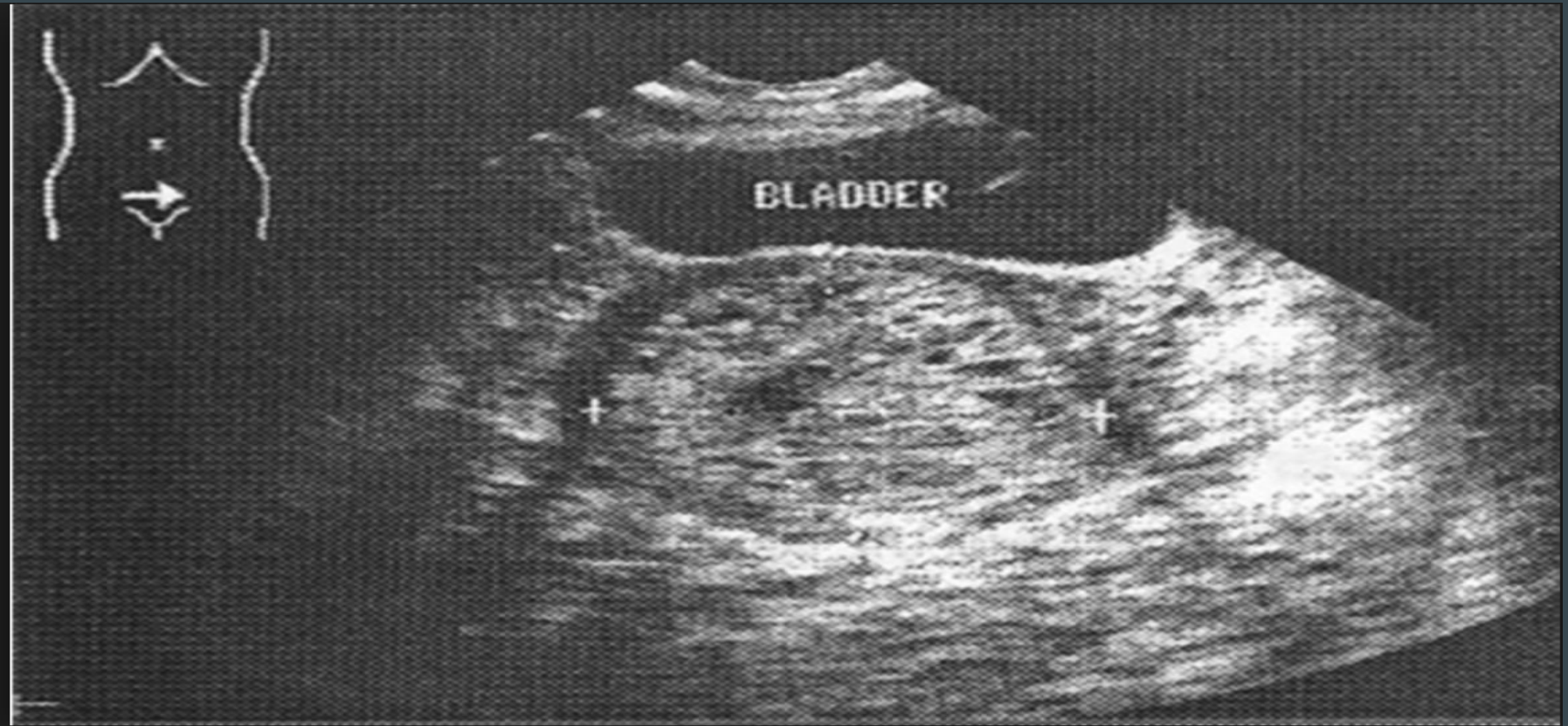# 18-Nasty headache in a patient with a hx of ADPKD



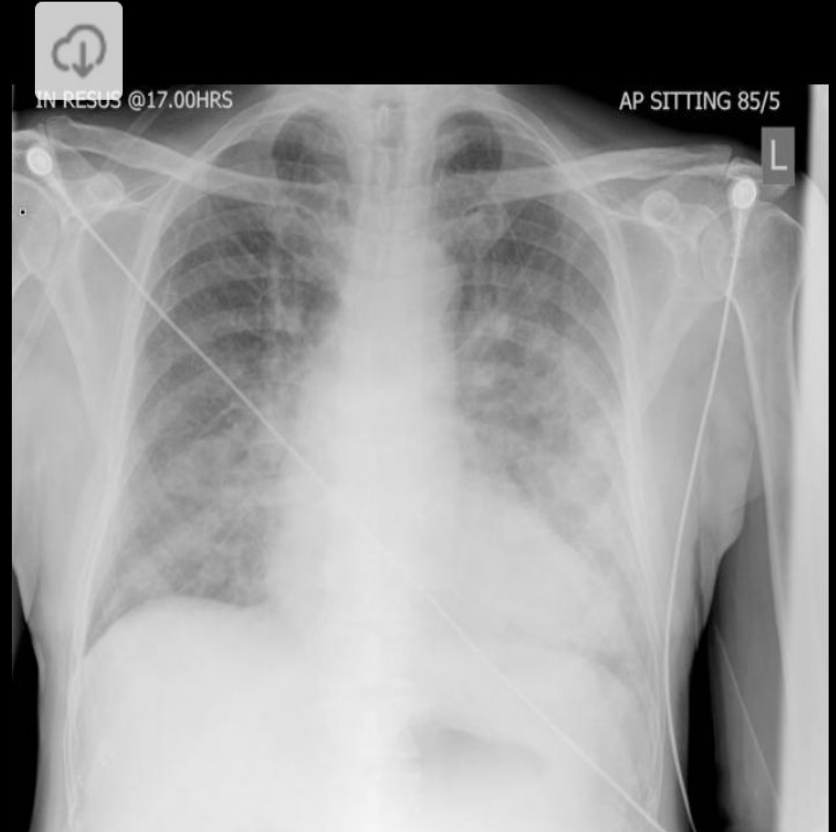

# 19A-Severe hyperemesis gravidarum



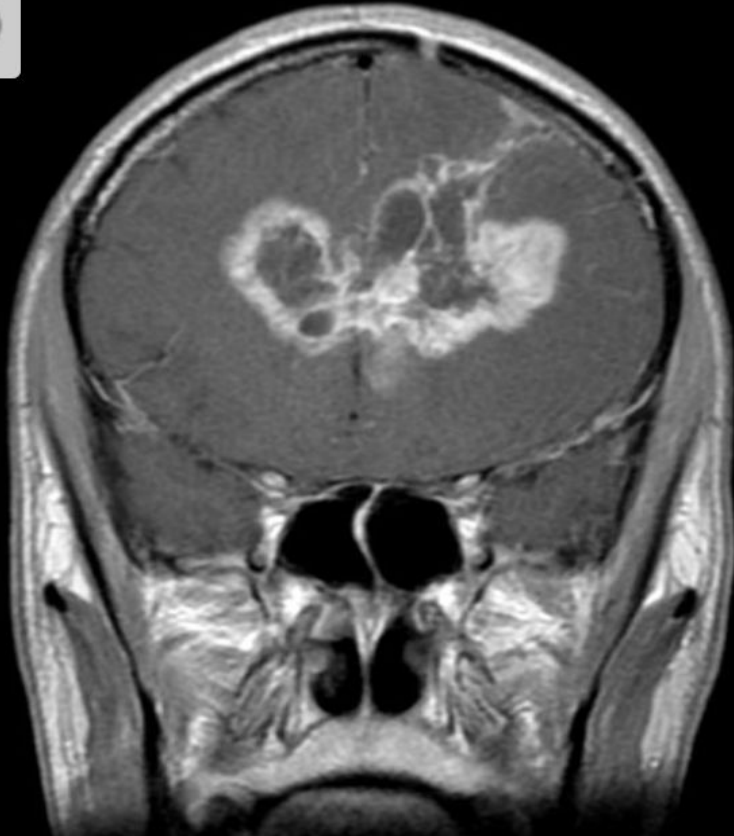# 19B-Snow Storm Appearance (researchgate.com)



# 20-History of CHF

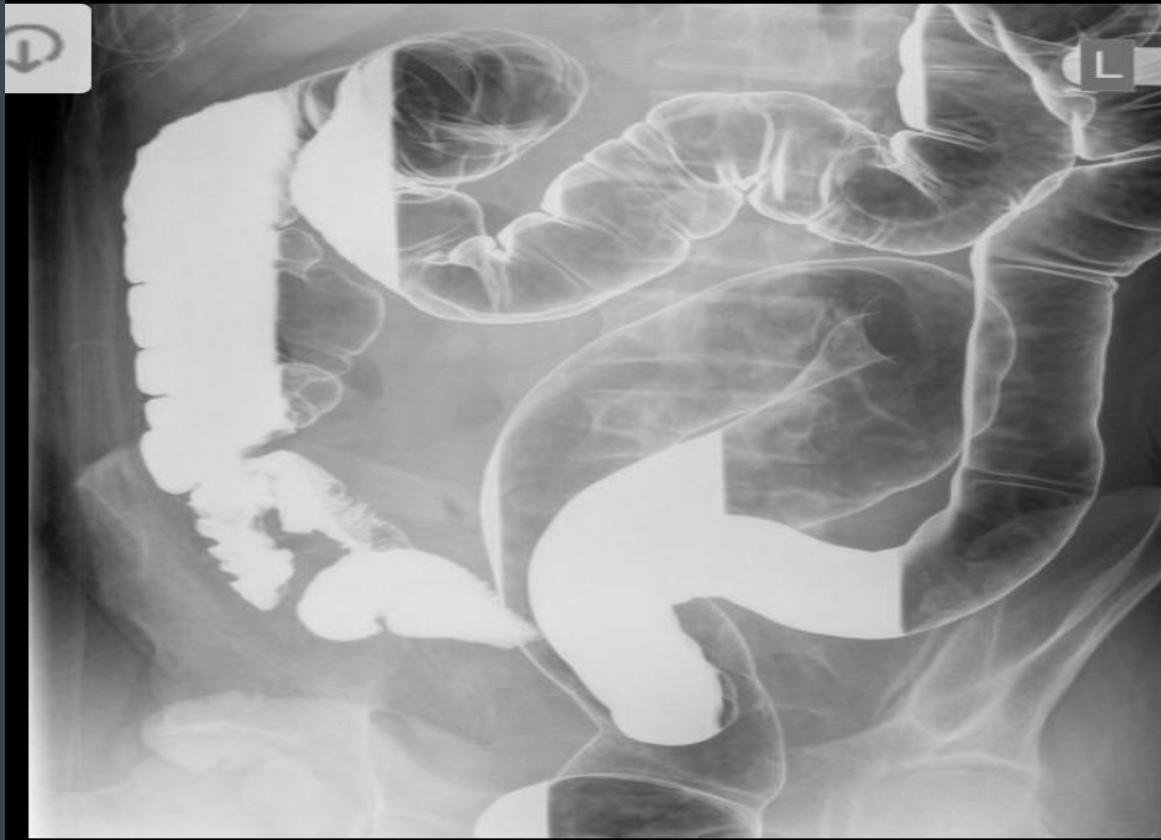


# 21-Severe headache over the past 6 mo

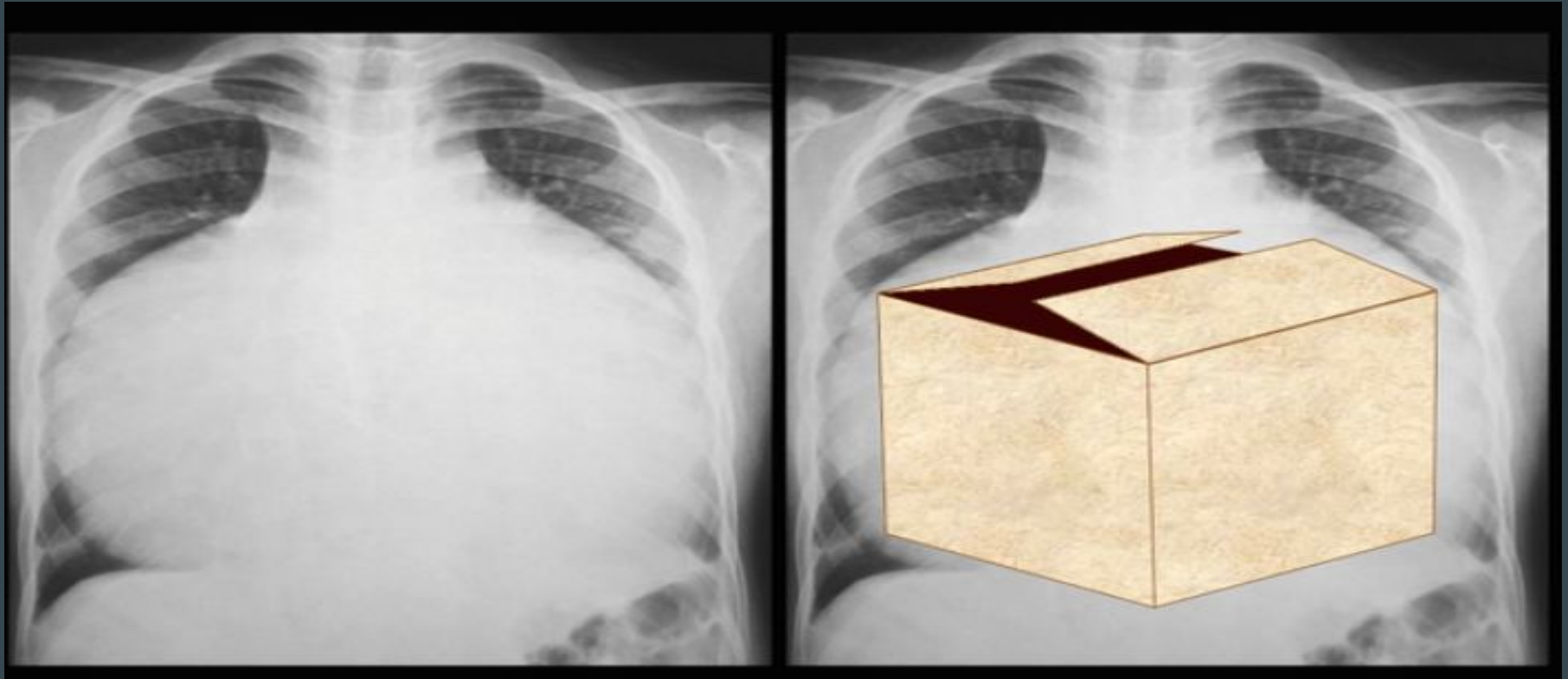




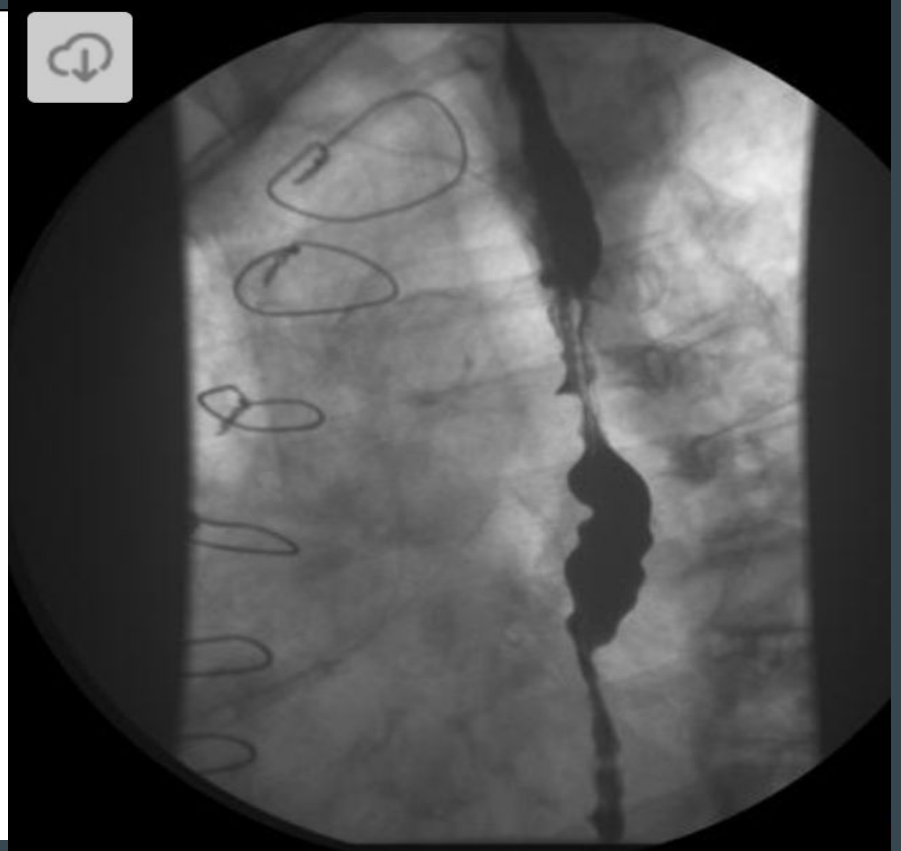
22-This patient also has a hx of Primary Sclerosing Chol.



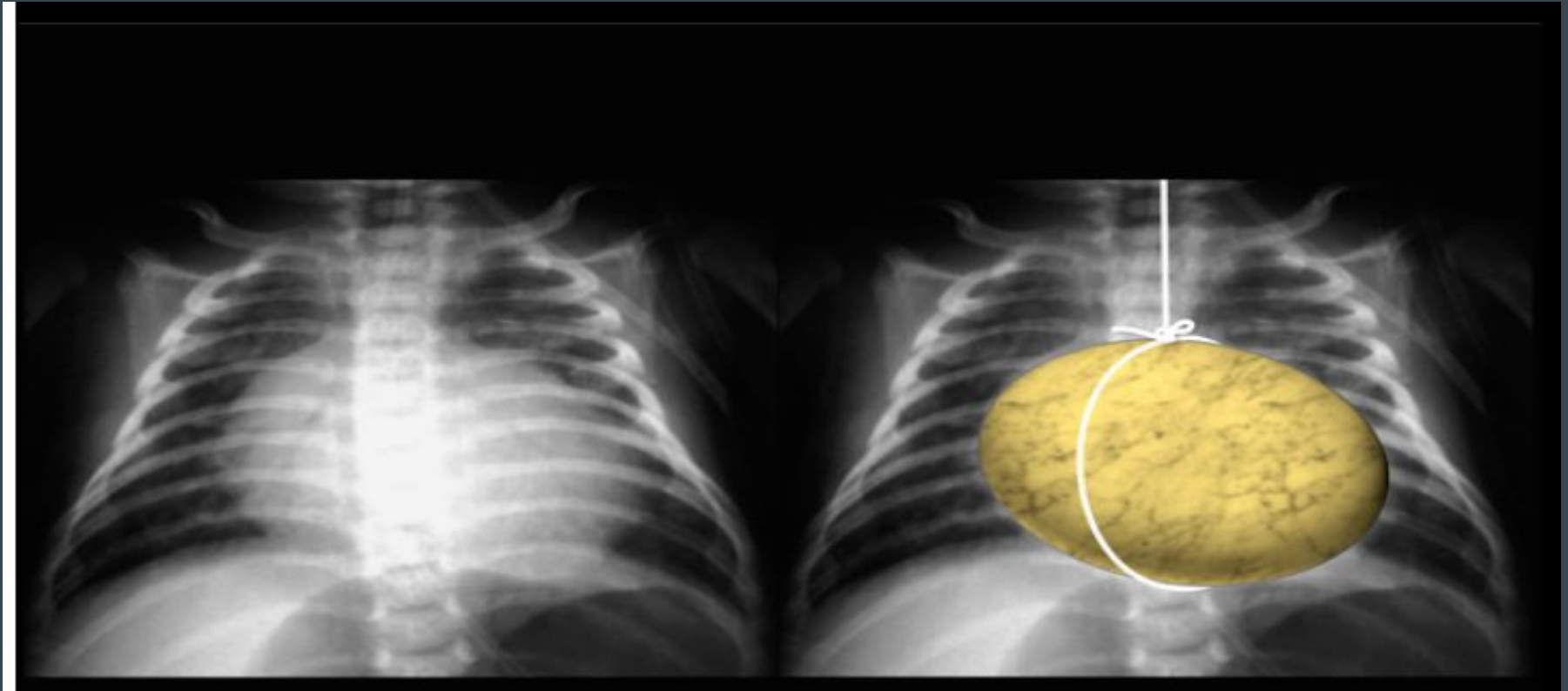
# 23-Mom took Li when she was pregnant for BPD



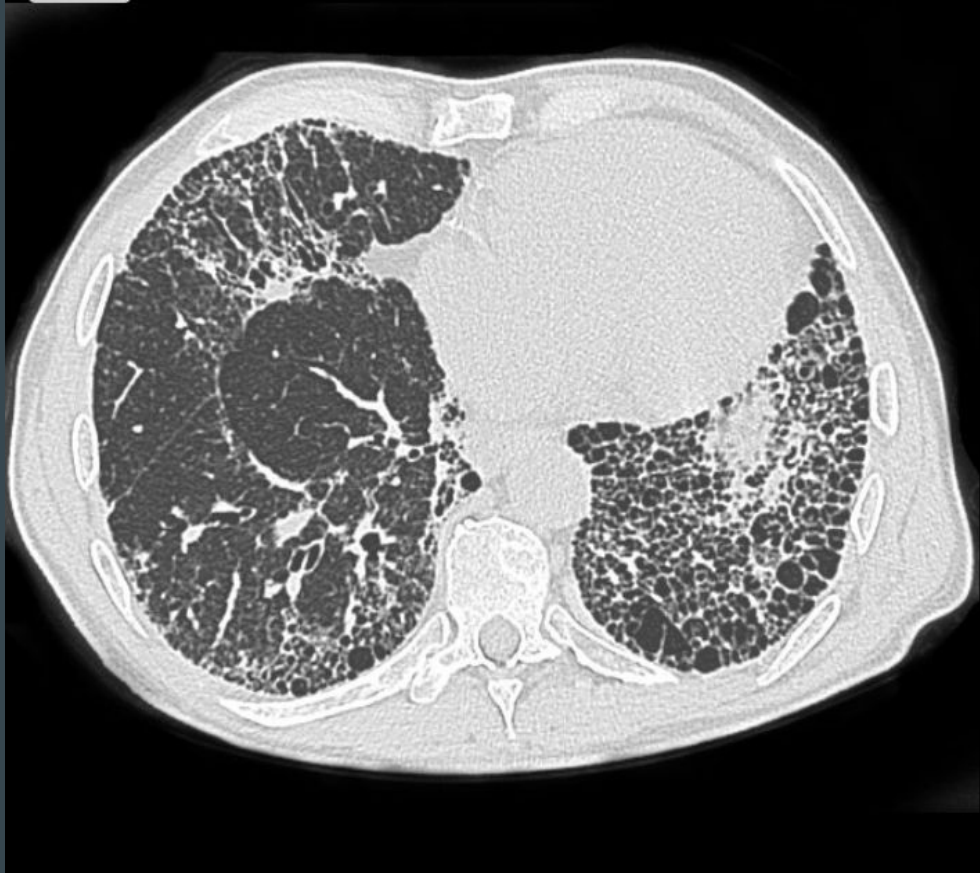# 24-Chest pain relieved with nitroglycerin



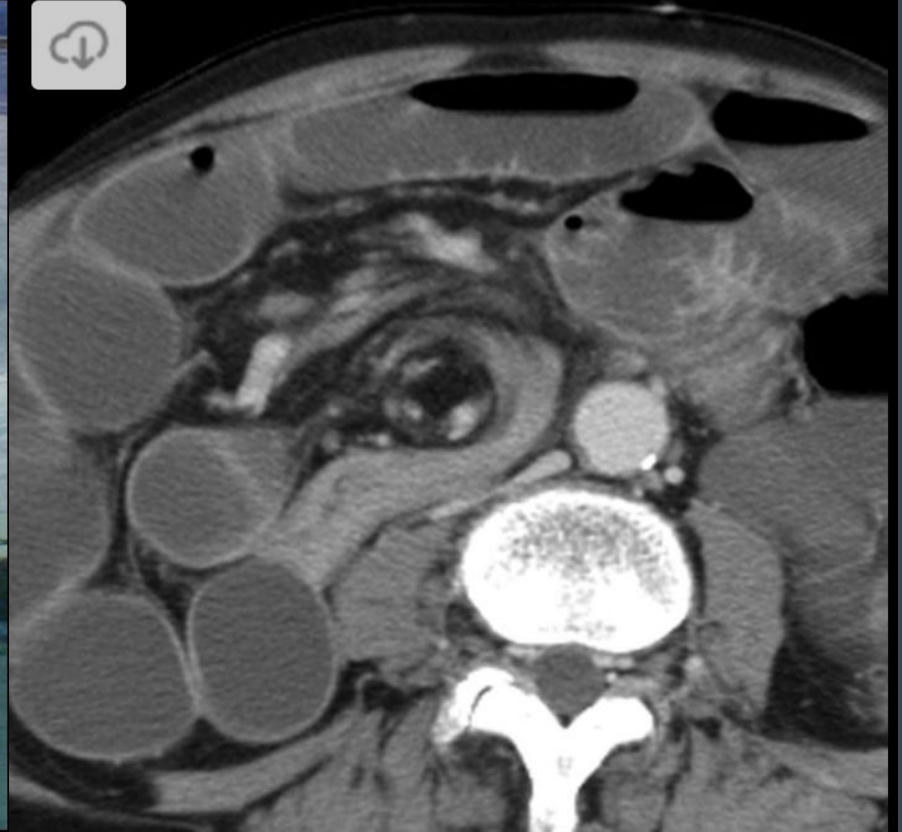
# 25-Newborn with cyanosis



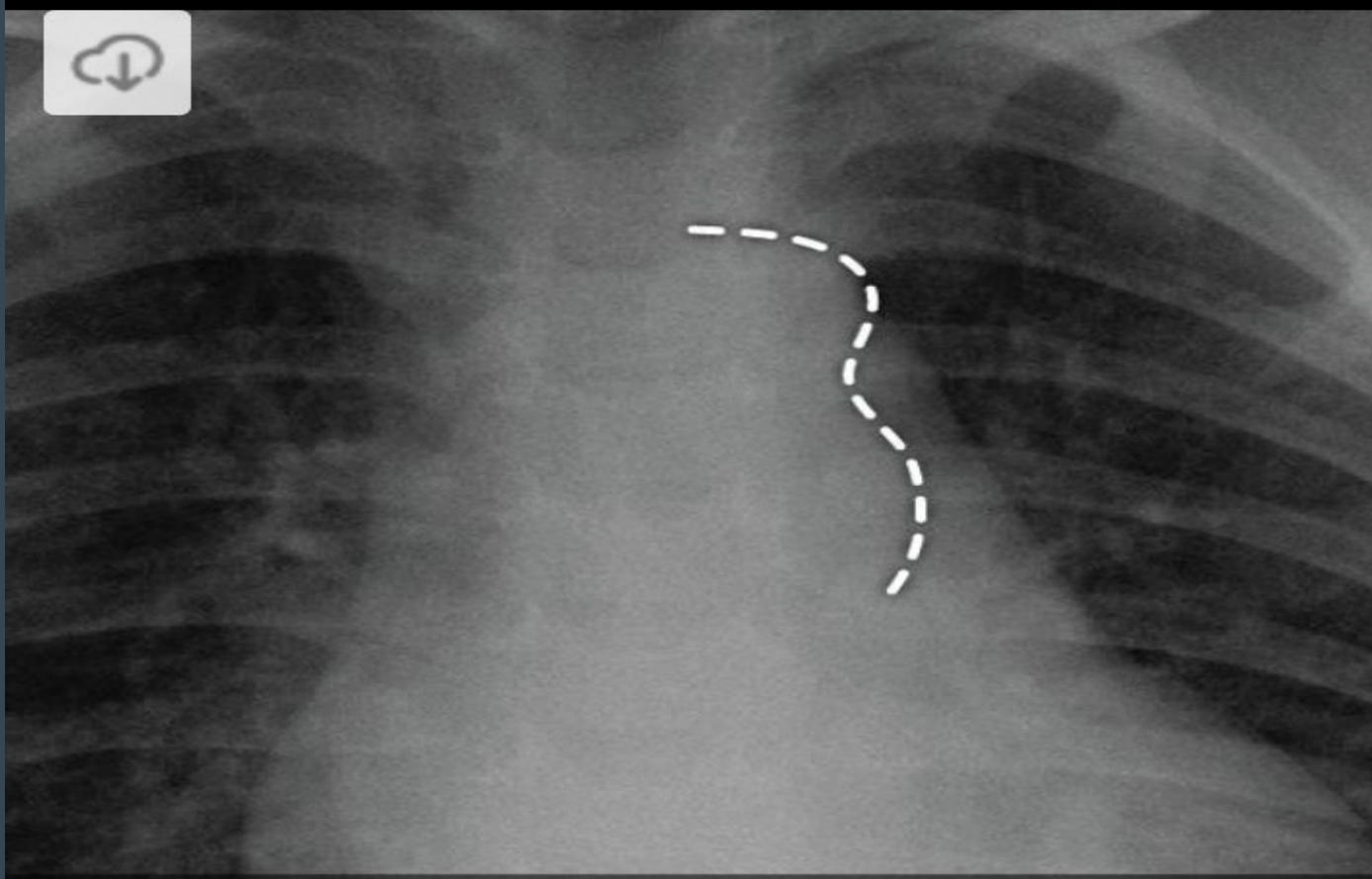
26-65 yo M with a 6 mo history of exercise intolerance



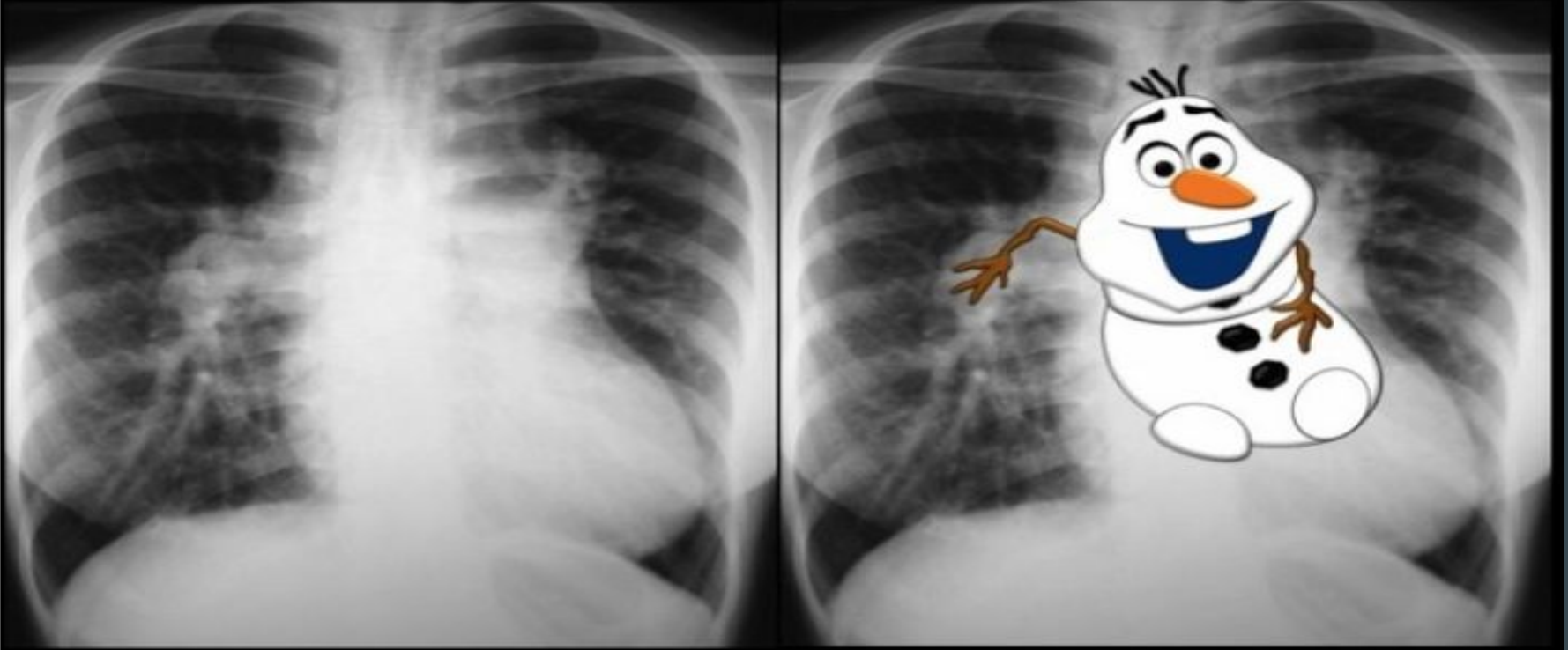
# 27-3 mo old with bilious vomiting



# 28-This patient has a history of Turner's Syndrome

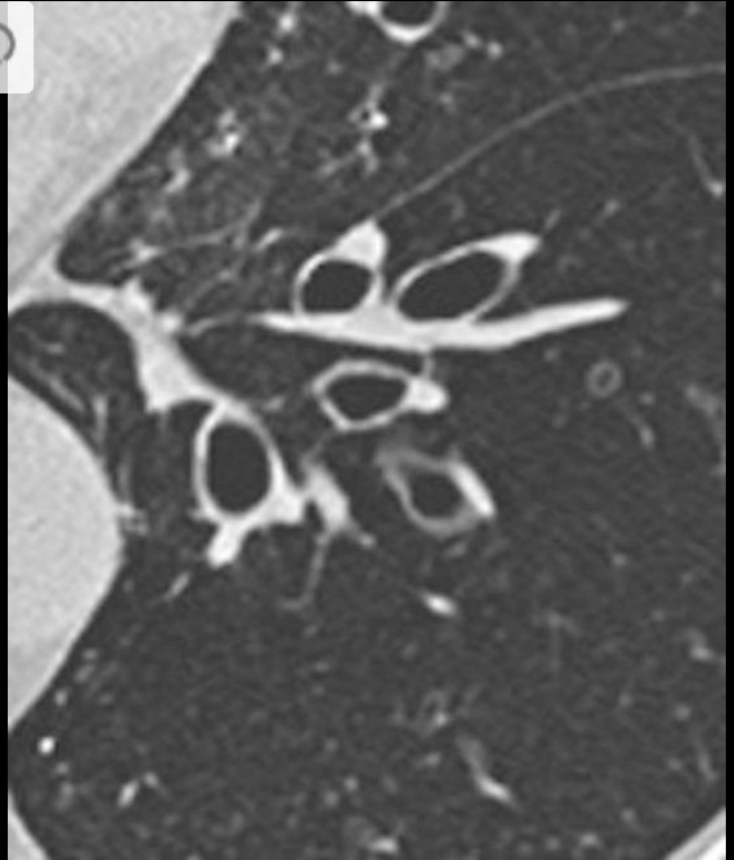


## 29-Newborn with cyanosis

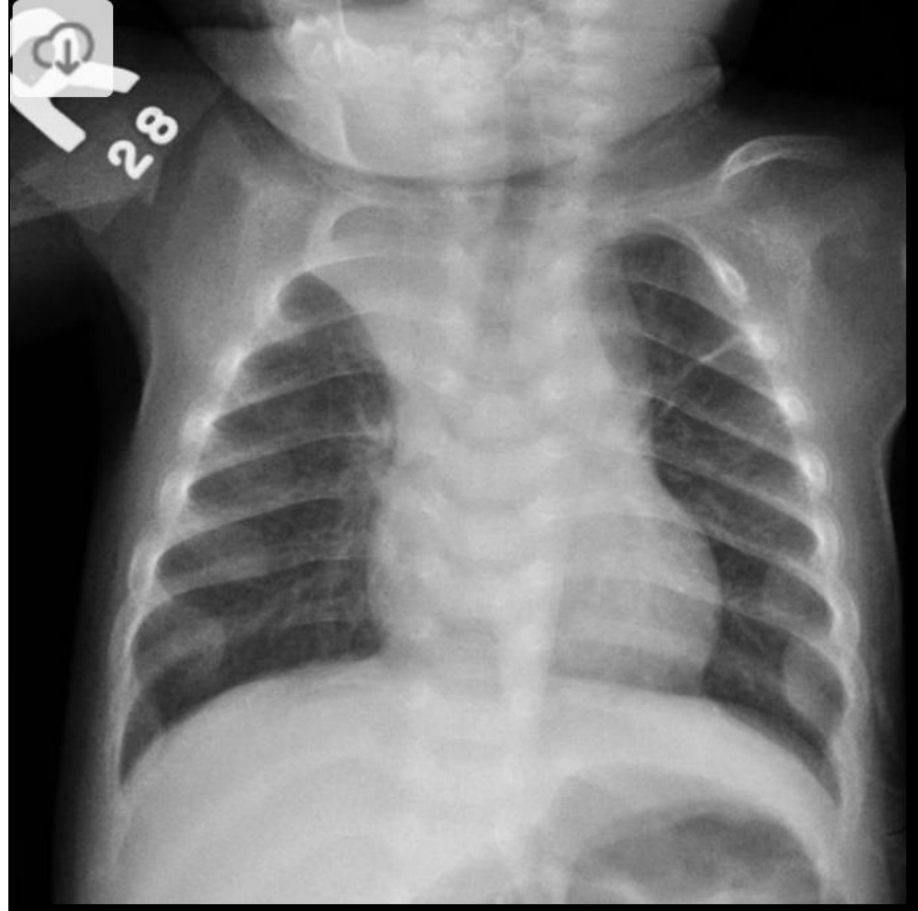



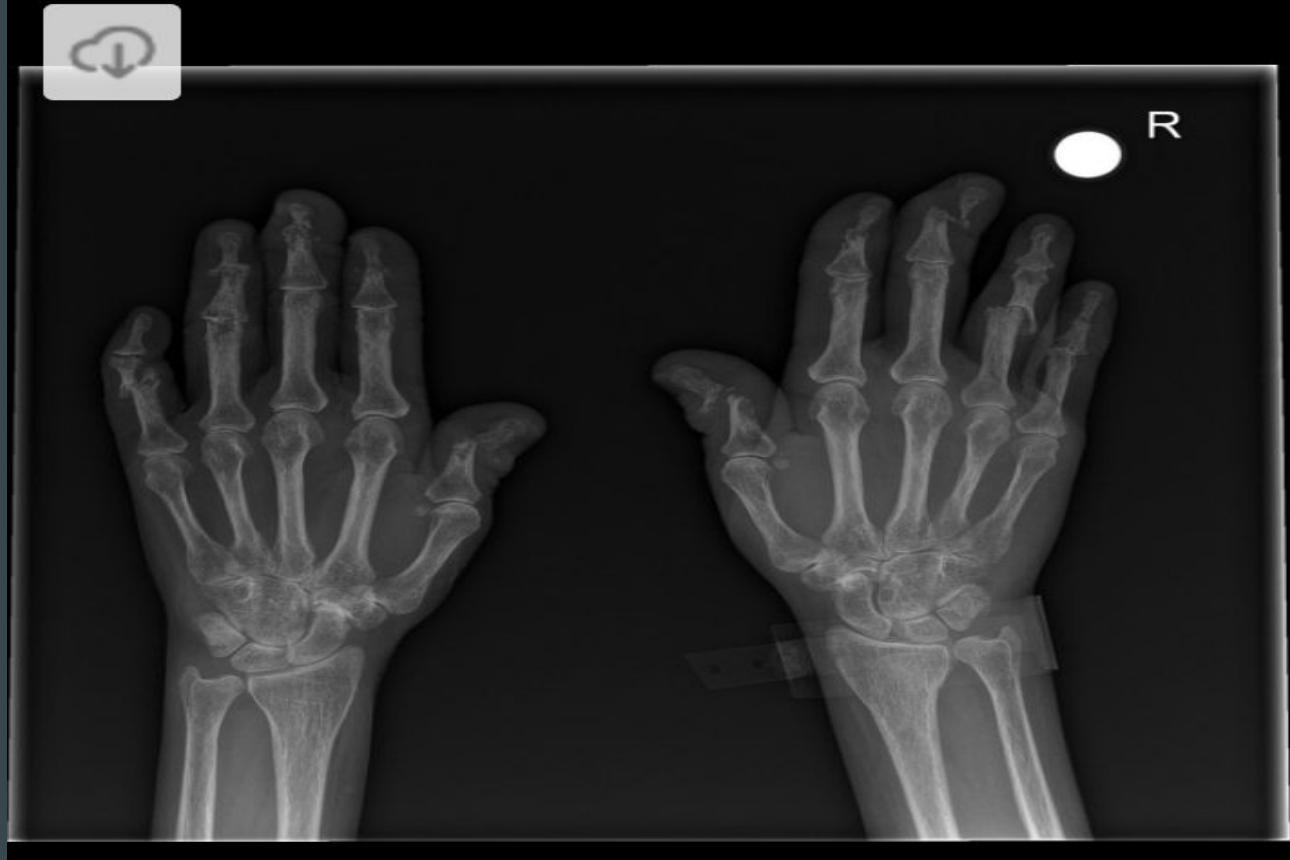# 30-This patient has a history of cystic fibrosis

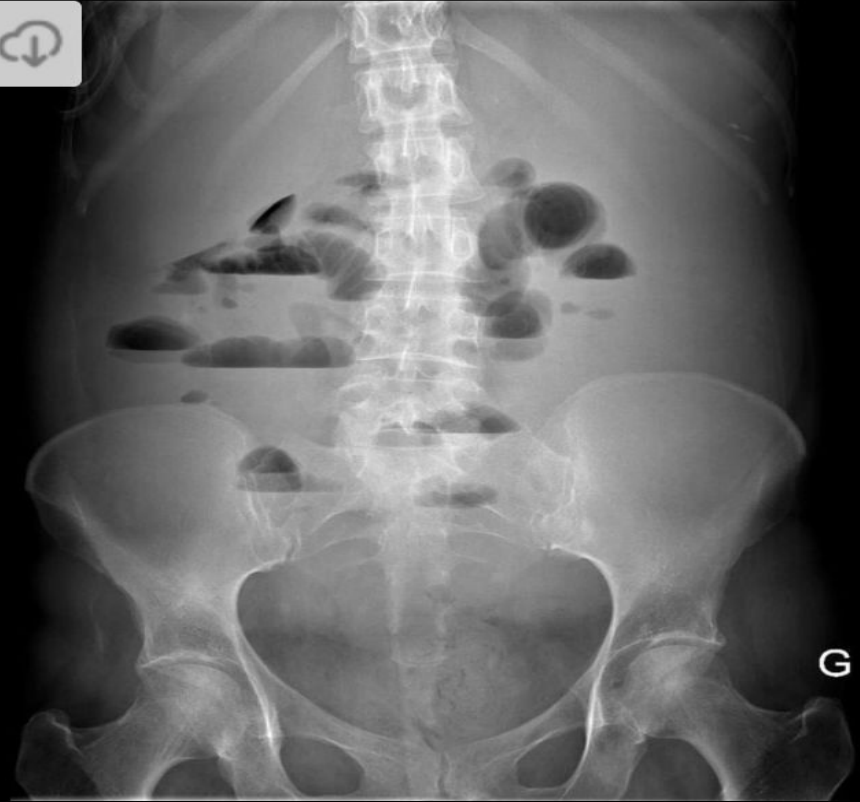

# 31-Elevated PTH, low Ca, and low Phosphate

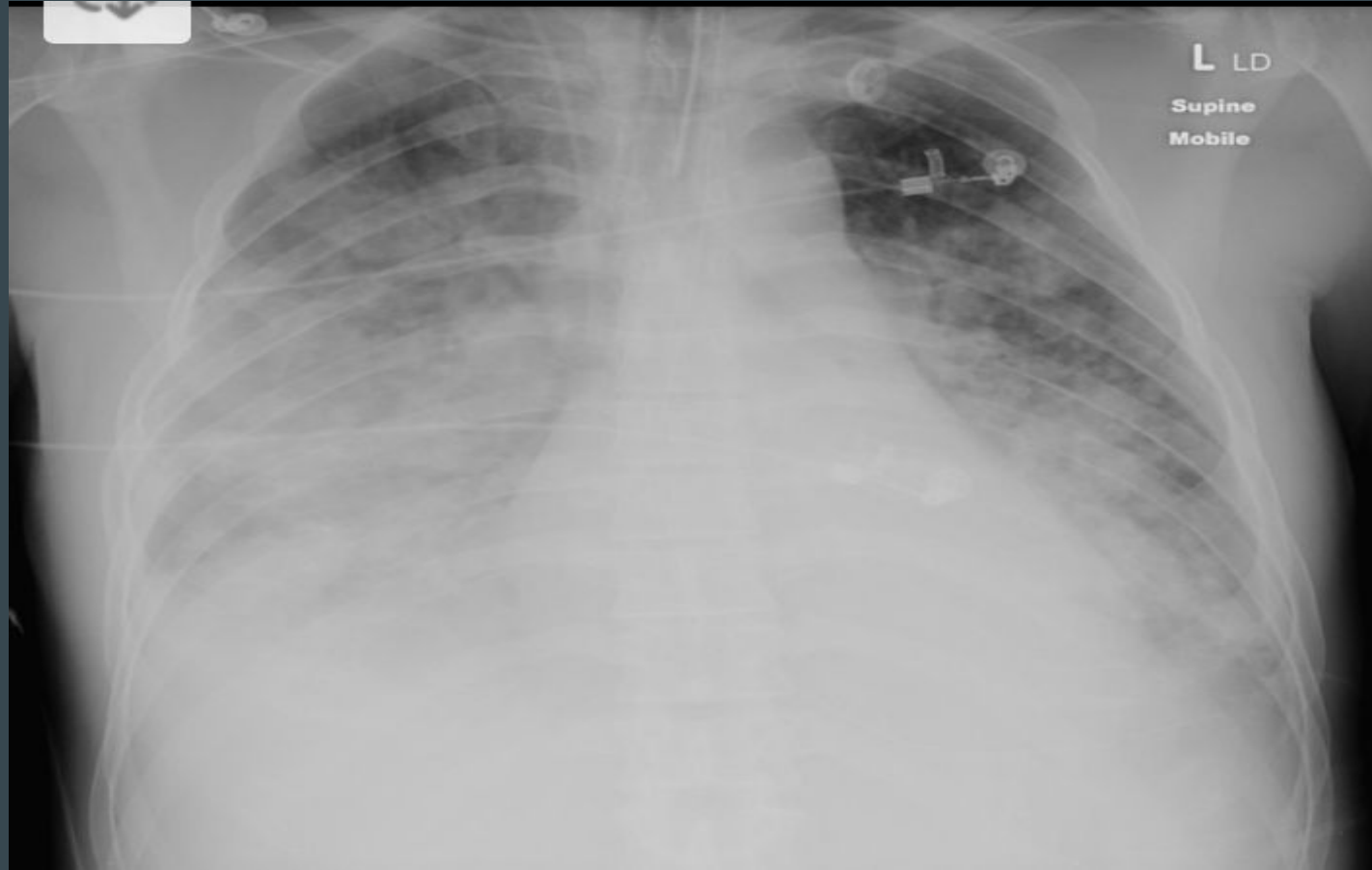


# 32-One of the seronegative spondyloarthropathies

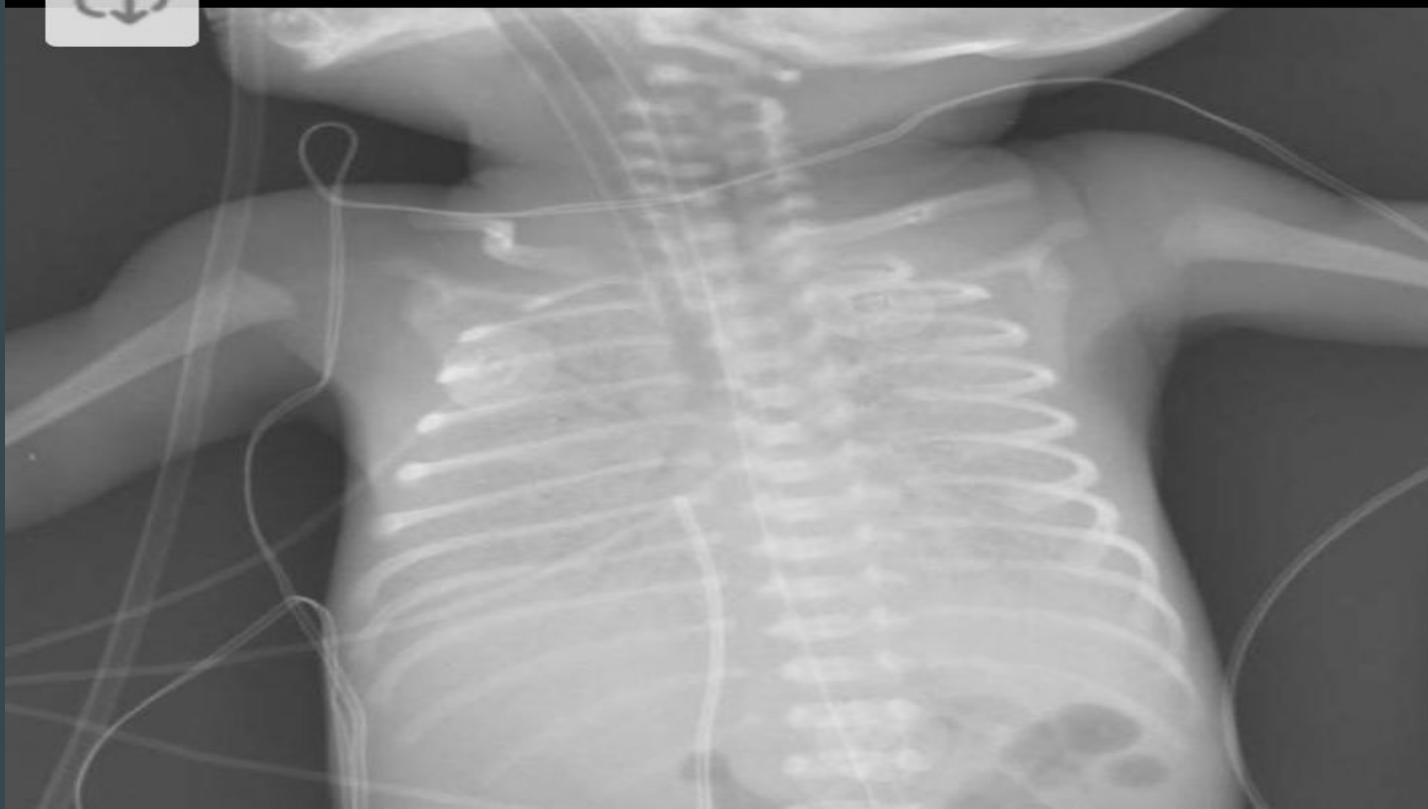



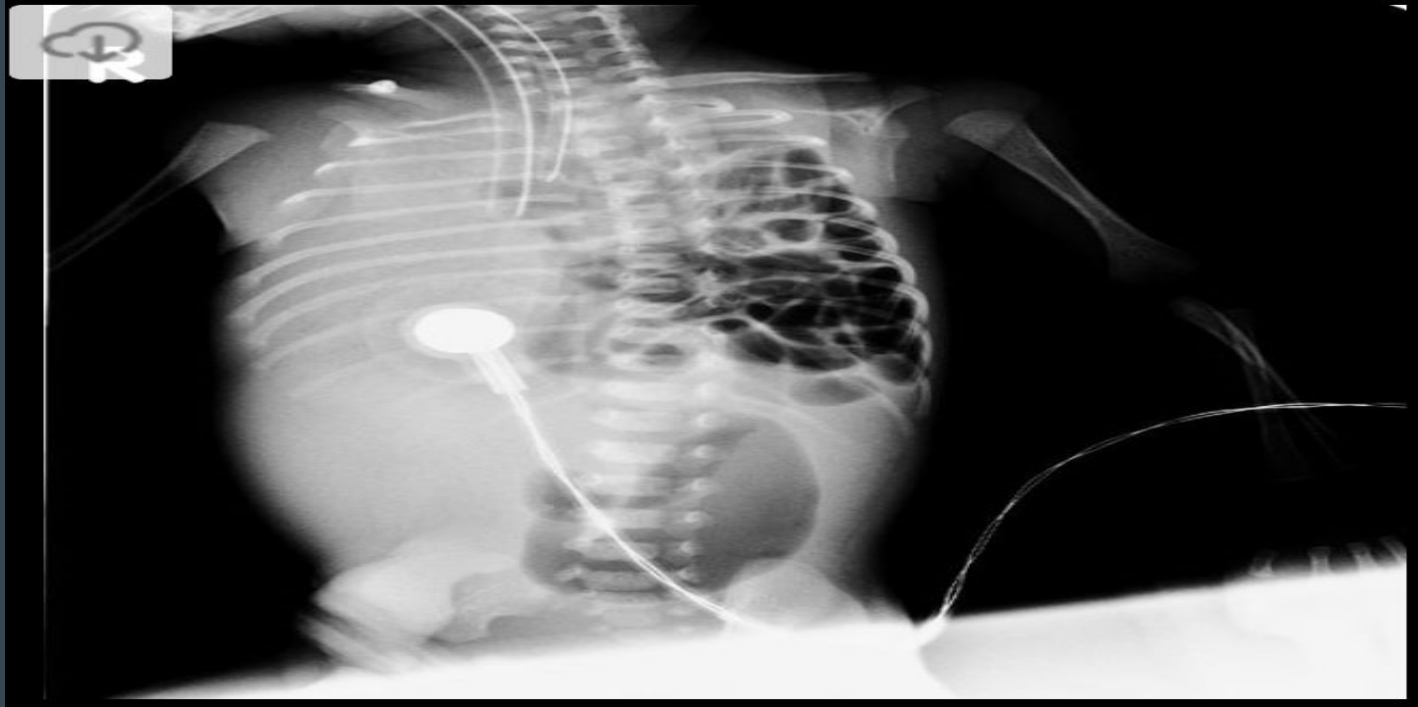
# 34-ICU patient placed on a ventilator



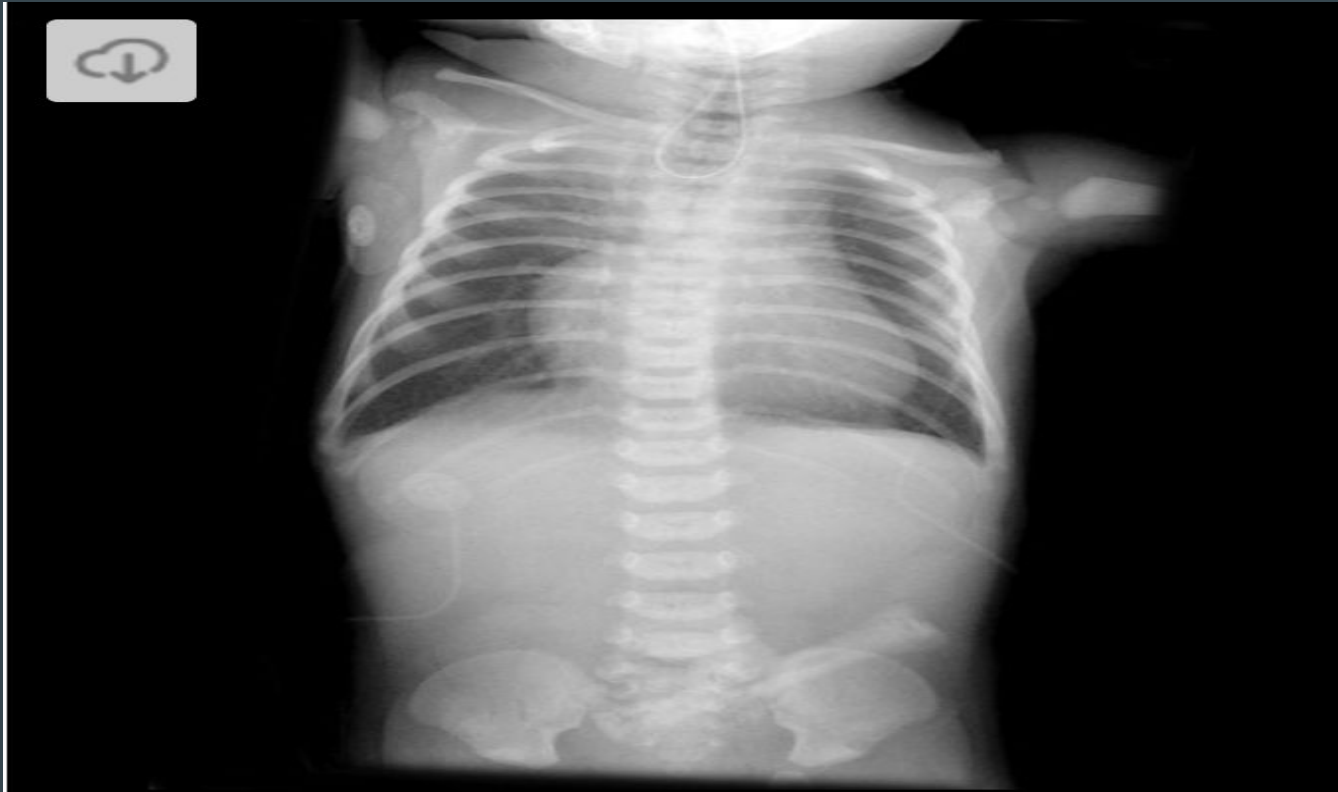35-Lecithin/Sphingomyelin ratio was 1.



# 36- Newborn with severe respiratory distress at birth

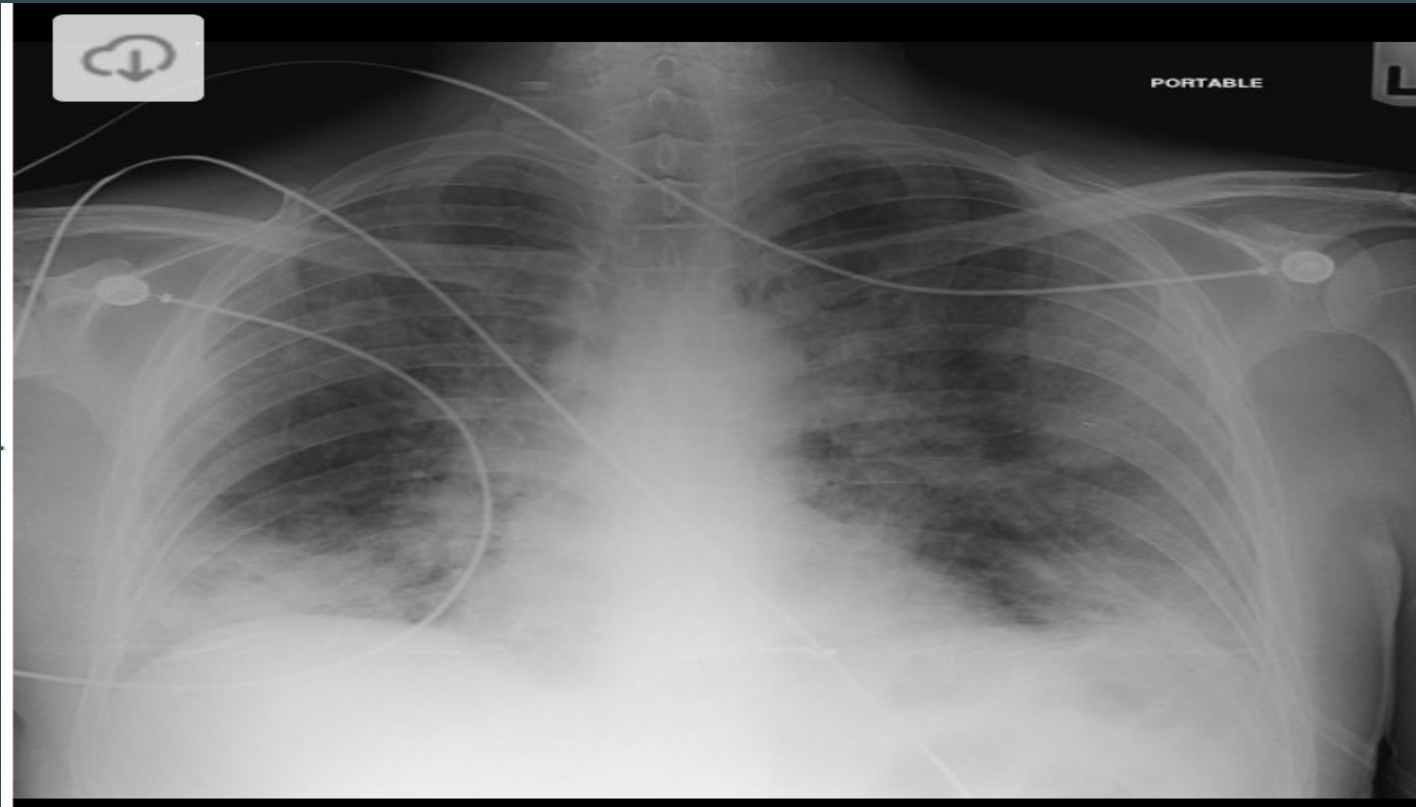


# 37-NGT Curling in the upper thorax





38-Obtained from a patient with a CD4 < 200.



# Reference

Images obtained from [Radiopaedia.org](https://radiopaedia.org).