

# Divine Intervention Episode 7

## Viral Cases C/Fungal Cases

...

Some MS4

1

Discussion of the Hepatitis Viruses (A-E). Key factoids relating to all Hepatitis Viruses. The Hep B serologies.

2

Bilateral facial erythema in a child. Stillborn fetus with generalized edema.

3

33 yo F presents with a 1 month history of post-coital bleeding. Colposcopy with biopsy reveals cells with enlarged nuclei and perinuclear vacuolation at the basal third of the cervix. Bug? Serotypes? Preventive strategies.

4

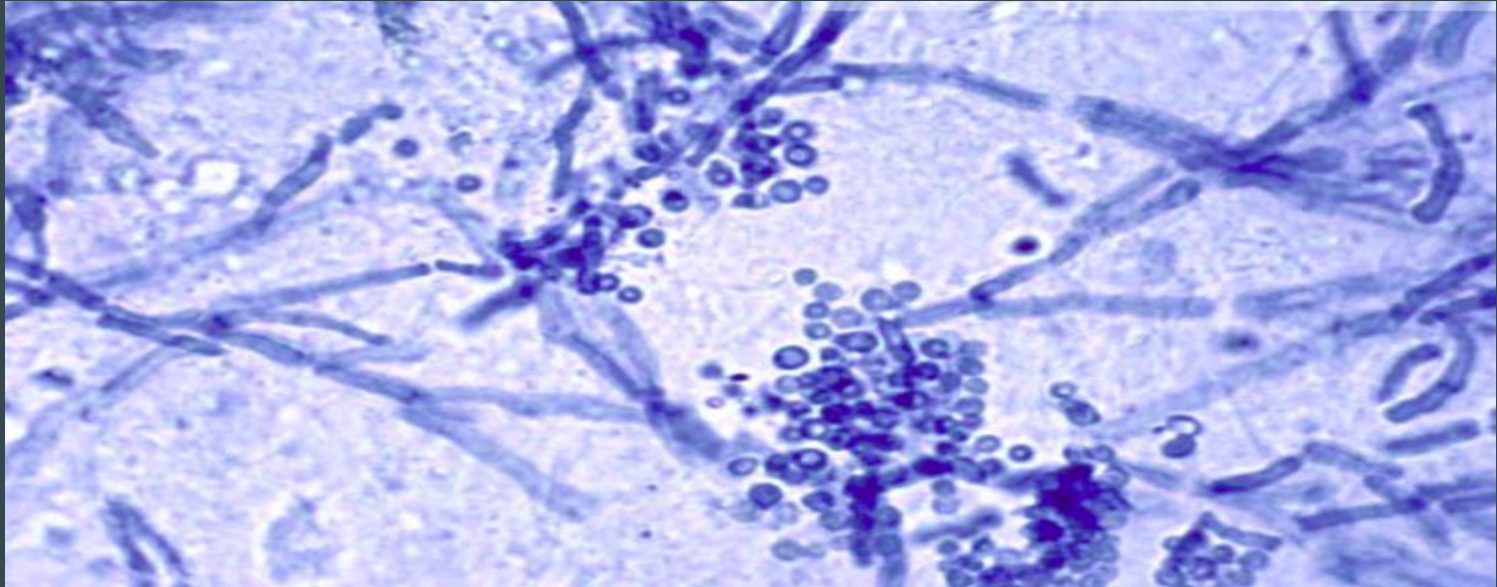
10 yo M who recently swam in a pool at a business retreat for all the executives at his dad's firm with other kids presents with a 4 day history of diarrhea and "red urine". He has a sore throat and bilateral, watery exudation from his eyes. Bug? Most common cause of viral gastroenteritis? Other associations.

5

Vomiting and diarrhea on a cruise ship. C. Difficile preventive strategies.

# 6

Farm worker presents with a mix of hyper and hypopigmented skin lesions on the trunk/back in the summer. Bug? Diagnostic testing? Finding on diagnostic testing? Treatment strategies.



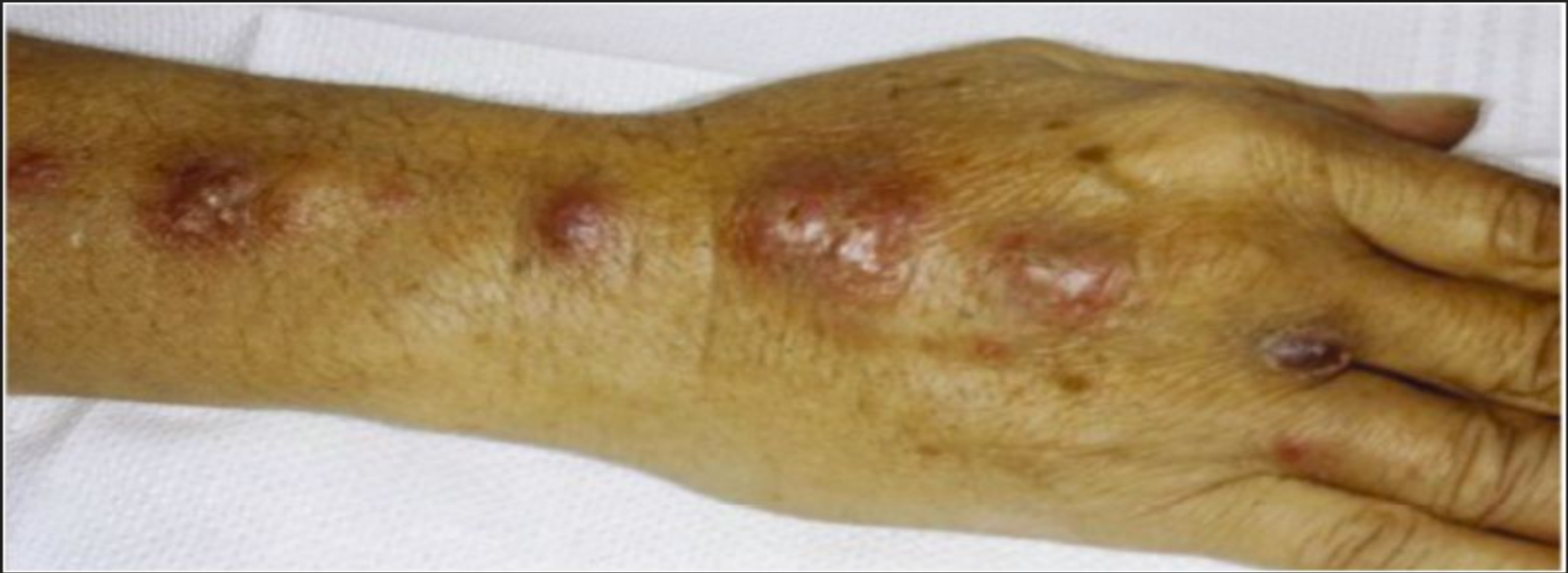7

10 yo M presents with a pruritic lesion on the left upper extremity. The lesion appears coin shaped with central clearing. This lesion fluoresces under Wood's lamp. Diagnosis? Bug? Quick discussion of dermatophyte infection associations.



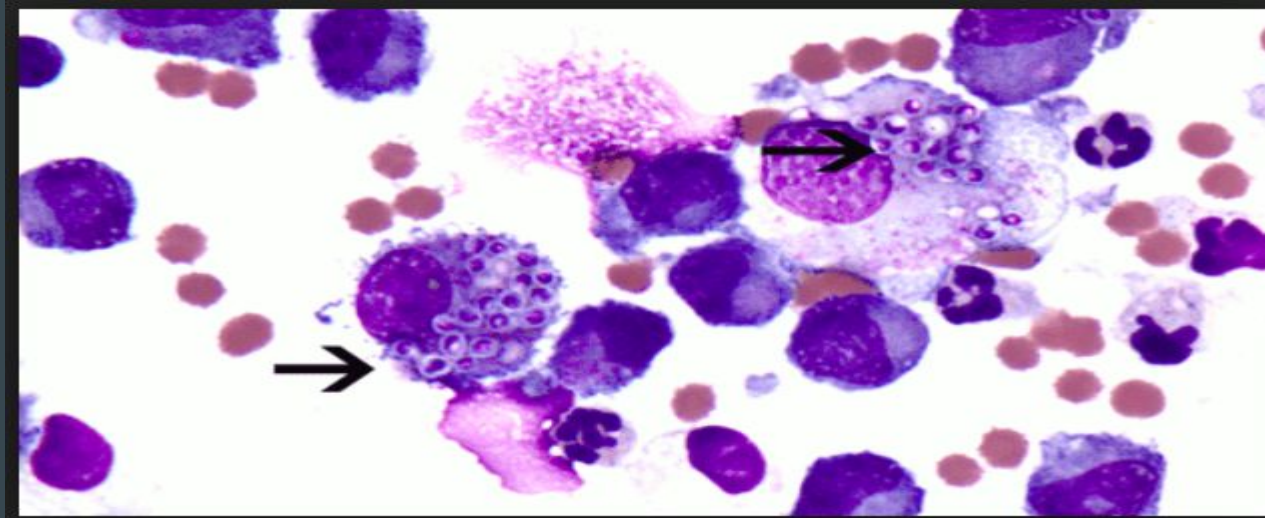
8

This patient was pricked by a thorn while taking a walk in his friend's garden.



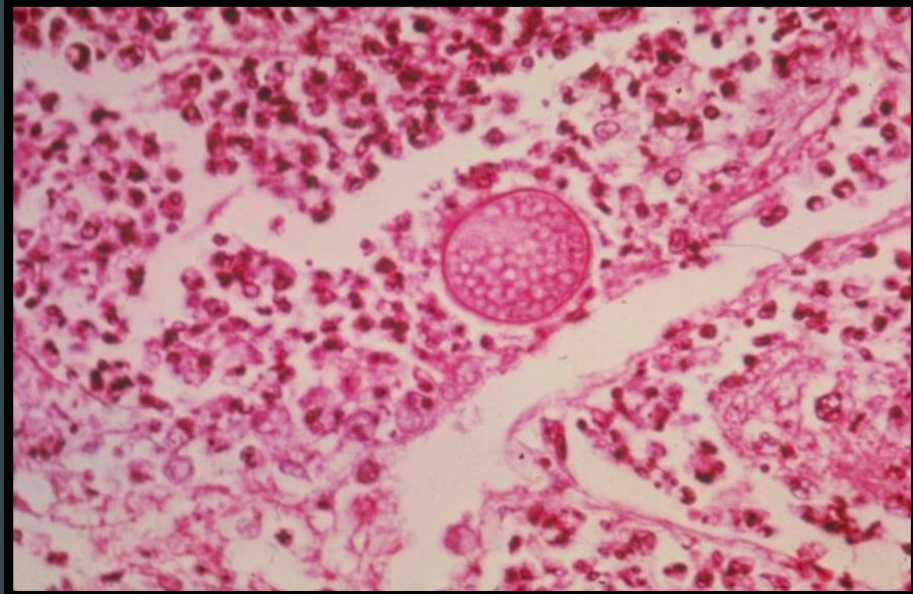
9

19 yo college student presents with dyspnea and a mild fever 1 week after returning from a field trip to the Mammoth caves in KY.



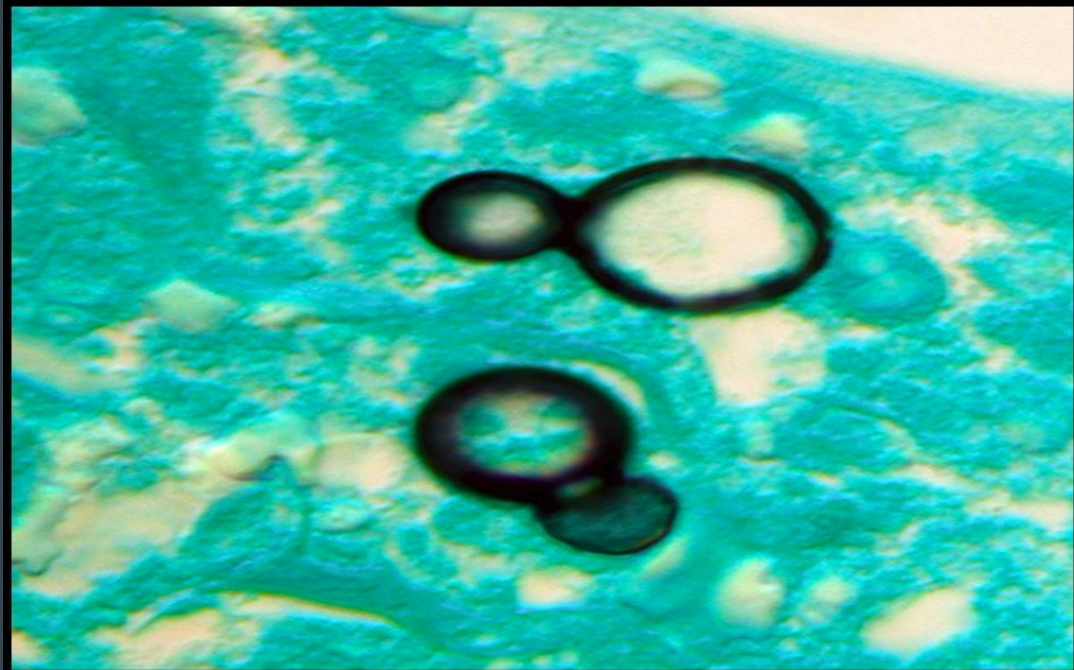
# 10

19 yo college student presents with a non-productive cough, mild fever, and painful, erythematous lesions on the shins bilaterally. The roof of his home in California was recently blown away by a countywide typhoon.



# 11

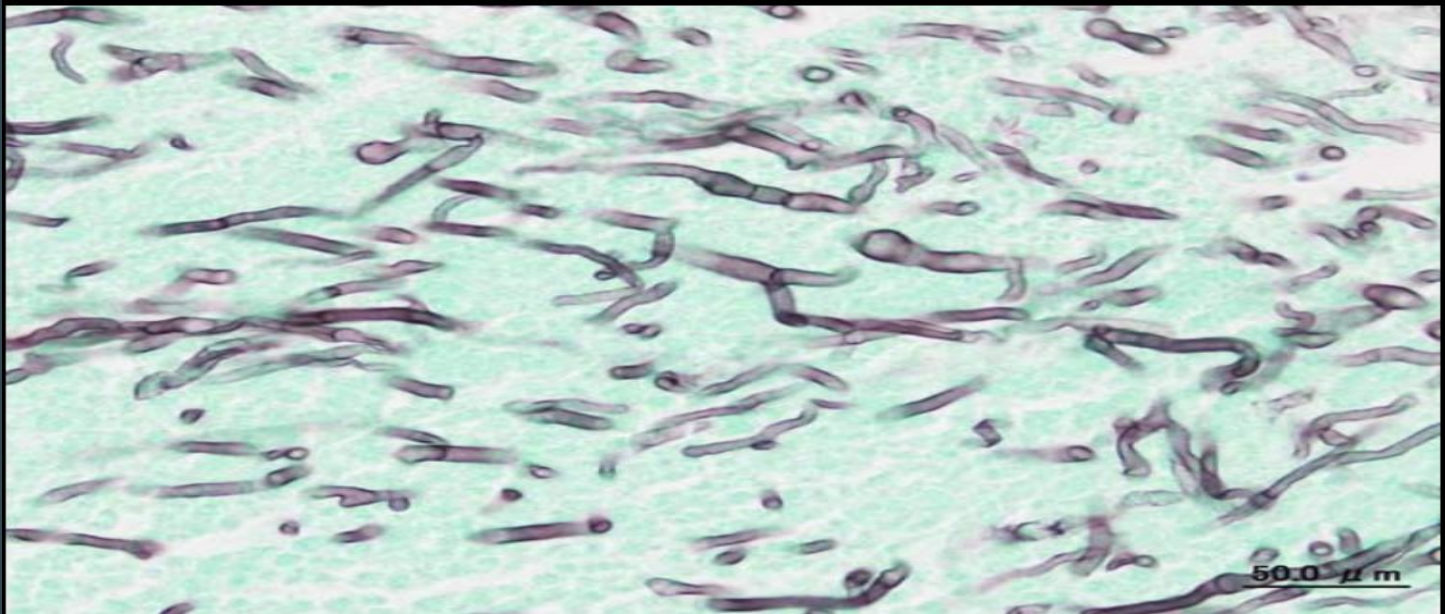
A resident of Missouri presents with a 2 week history of a non-productive cough and multiple ulcerating skin lesions on the UE and LE.





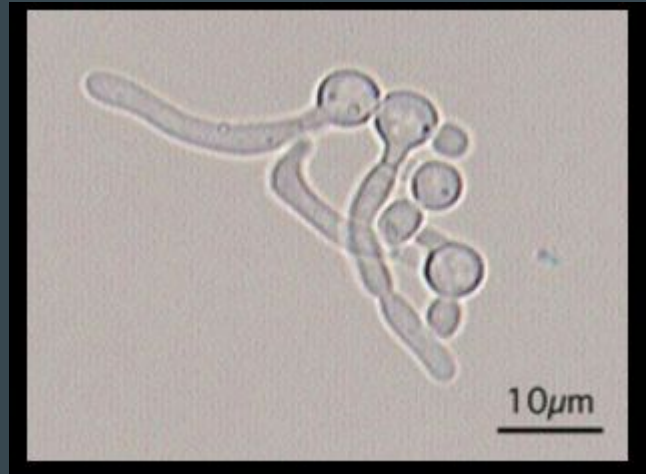
# 12

A patient with a past history of active TB presents with hemoptysis. Upright CXR is notable for an upper lobe lesion that changes position when a decubitus film is obtained.



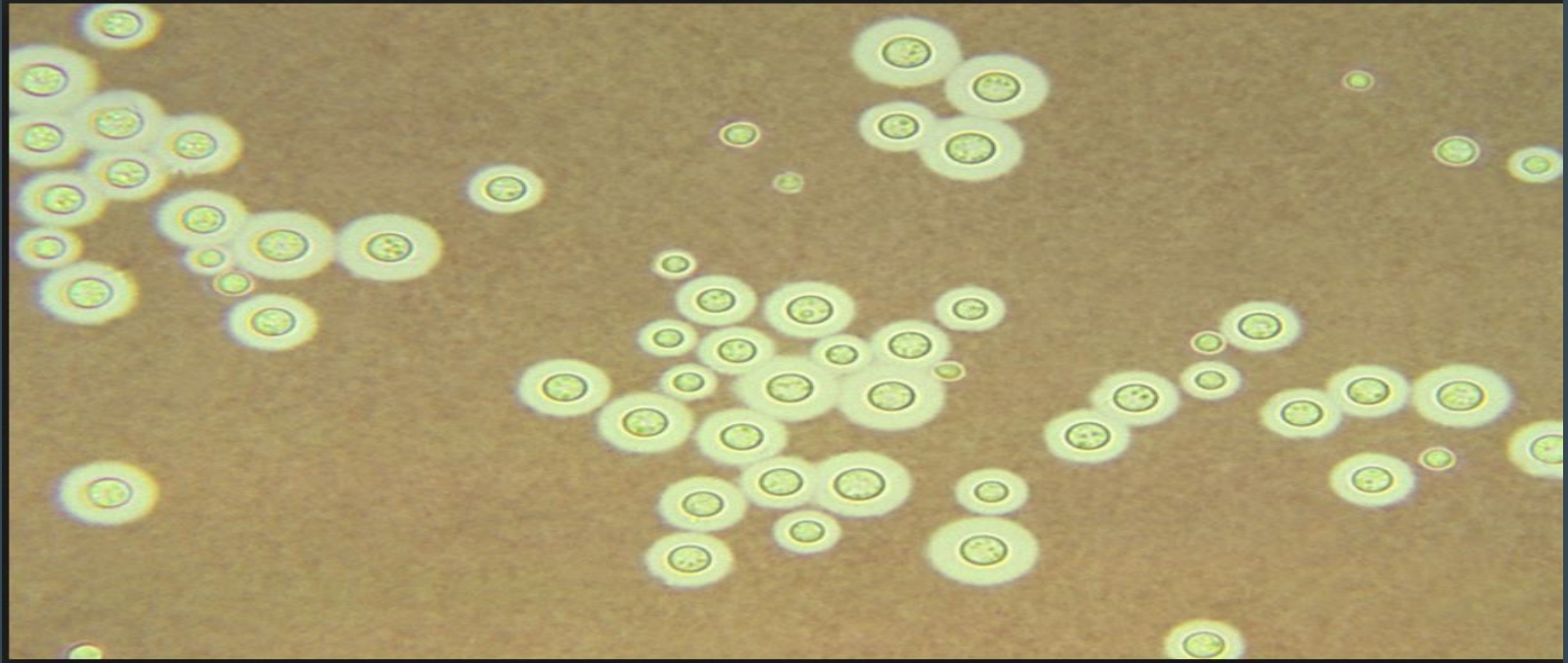
# 13

32 yo F who was recently treated for lobar pneumonia presents with severe vaginal and perianal erythema. A cottage cheese discharge is seen on vaginal exam.



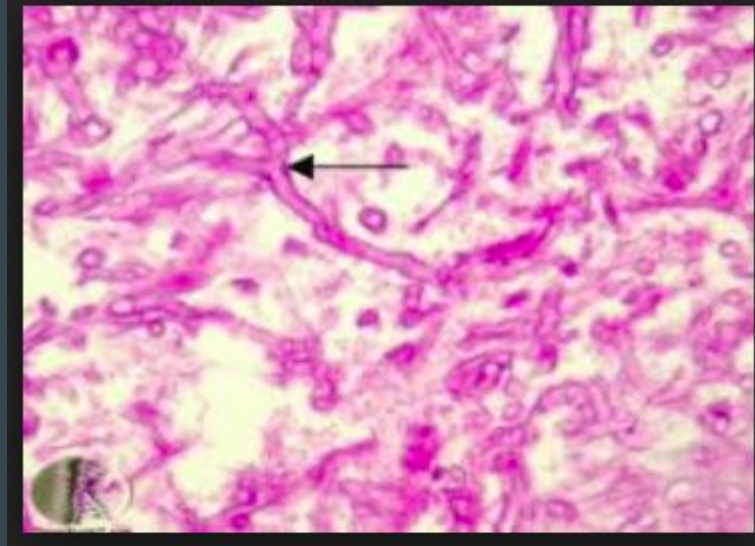
# 14

Fever, nuchal rigidity, and papilledema in a patient with a CD4 count of 93 who runs a pigeon farm.



# 15

33 yo M has been in the ICU for the past 7 days. He was rushed to the hospital by ambulance after he was found obtunded by a close friend at home. CBC/BMP on admission showed a blood glucose of 300, pH of 7.13, and  $\text{HCO}_3^-$  of 13. He has been recovering over the last 3 days but begins to complain of severe facial pain in a maxillary nerve distribution. Over the next few hours, he begins to drain black, foul smelling material from his nostrils.





# 16

A patient with a CD4 count of 45 presents with a 1 week history of shortness of breath and a non-productive cough. T is 100.9. A CXR is notable for bilateral interstitial infiltrates with a ground glass morphology. LDH is markedly elevated. Diagnosis? Other associations with this bug.

